The Haug Report

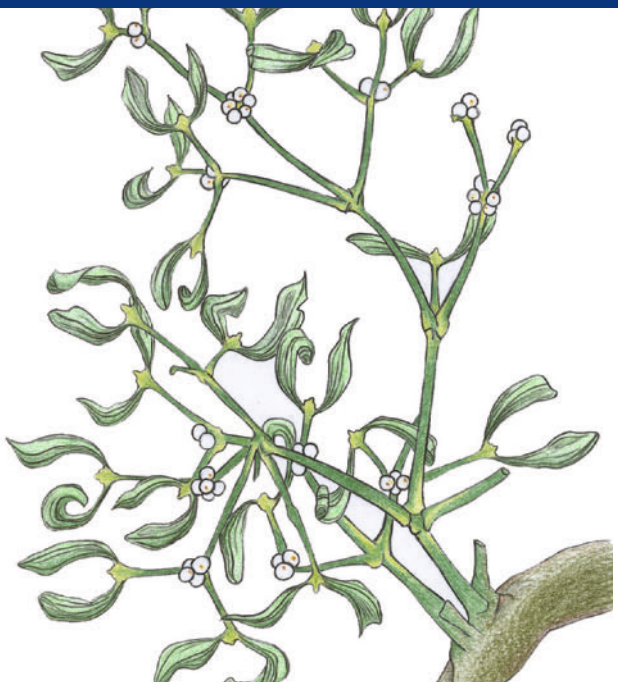

Mistletoe Injection Therapy and the Locomotor System

A holistic treatment concept for osteoarthritis and degenerative spinal disorders

Dr. med. Kurt Jürgen Zell

Haug

The Haug Report

Published with the support of
Helixor Heilmittel GmbH

Helixor
Bringing life to life.

Imprint

The Haug Report
Mistletoe Injection Therapy and the Locomotor System
January 2020

This issue of the Special Treatment Report was created with the support of Helixor Heilmittel GmbH.

Publisher
Georg Thieme Verlag KG
Rüdigerstraße 14, 70469 Stuttgart

For the publisher
Joachim Ortleb
E-Mail: Joachim.Ortleb@thieme.de

Typesetting
Fotosatz Buck, Kumhausen

Title image
© Dr. med. Kurt Jürgen Zell

Image credits
© Dr. med. Kurt Jürgen Zell (except ▶ **Fig. 1, 2, 3, 34, 47, 48**), Gaby Günter (▶ **Fig. 1** and **3**), Fotolia/psdesign1 (▶ **Fig. 34**), Ralf Knoeringer (▶ **Fig. 47**), Erich Jöckel (▶ **Fig. 48**)

Acknowledgment

This booklet is the product of 39 years of medical practice. First, I would like to express my gratitude to my patients, without whom those years of experience would never have been possible. They are all, without exception, unique human beings – and not standard patients, as evidence-based medicine would have us believe.

Biological medicine adopts a bio-logical perspective of humans, nature, and the cosmos. Consequently, the whole is always more than the sum of its parts, as Aristotle recognized millennia ago. Above all, I am and will always be grateful to that grand design and the powers that govern it.

For the preparation of this publication, another excellent source of support was the assistance I received from Helixor Heilmittel GmbH, a pharmaceutical company for holistic, integrative medicine. Especially from Eva Susanne Klein at Helixor, who supervised this project. Dr. med. Dietrich Schlodder and Dr. med. Christfried Preußler supported me with their expertise on mistletoe and Anthroposophic Medicine. I would like to thank Helixor as well for providing illustrations by Elizabeth Pich, photography by Ralf Knoeringer, and graphics by Gaby Günter. I am also grateful to Dolores Konnerth and Barbara Schwarte for their support.

Furthermore, I would like to thank Klaus Stuttmann for the wonderful illustration entitled “Reform gymnastics” and my friend Erich Jöckel for his photography. And Nadine Schuh for her drawings. My brother-in-law, Dr. med. Karl-Heinz Teusch, whose experience encompasses both surgical and conservative approaches, supported me with his knowledge of a number of orthopedic topics where my own experience was limited.

Several friends supported me with advice during the writing process; Peter Treitz provided initial editing and improved the mechanics of the text.

I want to thank Jacqueline Schmidt from Thieme Media and her assistants for their excellent support.

Finally, I am especially indebted to my wife, who has always followed my work and enriched it with her ideas. Most of all, for her boundless patience for the many hours that my work has kept me away from home.

Saarbrücken, spring 2017

VITA

Dr. med. Kurt Jürgen Zell studied human medicine in Homburg, Saarland, from 1974–1980. He completed his residency in the Orthopedic Department of the Saarland University Hospital Homburg in 1987. From 1987–2001, he was a member of the joint orthopedic practice Dr. med. Ecker/Dr. med. Zell in Idar-Oberstein. In 2002 he established his practice for biological medicine in Saarbrücken, where he continues to treat patients.
Dr. Zell has extensive experience in holistic medicine, particularly in the treatment of acute, chronic, and degenerative locomotor disorders. He gives seminars on this topic, mainly in conjunction with therapies that rely on mistletoe and Christmas rose extracts.
Internet: www.doktorzell.de
E-mail: kj.zell@web.de

Foreword

For ages, the white-berry mistletoe has been used as a medicinal plant for a broad spectrum of indications, comprising nearly all diseases with hardening processes – whether morphological (cancer or arteriosclerosis), functional (spasms), or psychological (chronic pain or depression).

This specific healing potential is written into the anatomy of mistletoe: even on older specimens, its branches remain green and supple and do not grow woody with age. Where the first signs of aging appear, such as calcium oxalate crystals in older stems, the plant responds with clusters of berries. Mucous in the berries paves the way for new life that shoots out from the hardened stem after successive stages of mucous formation and softening. The dissolution of hardening as an endogenous trait – just one of the signature healing properties of mistletoe.

Another signature can be found in the unique response of the winter-active evergreen plant to warmth. Delicate mistletoe tissue resists even strong frost by injecting its own "anti-freeze" into the vascular tissue of its host. This allows the mistletoe bush to maintain a viable water supply in winter. Given these properties, it is hardly astonishing that the injection of mistletoe extract triggers a local thermal reaction, depending on the administered dose. Mistletoe is predominantly used to treat multiple forms and stages of cancer diseases. Yet in addition to this sphere of treatment, degenerative joint and spinal disorders are another promising and proven indication. While the primacy of mistletoe therapy in cancer treatment can be attributed to the founders of Anthroposophic Medicine, *Rudolf Steiner* and *Ita Wegman*, it was *Dr. med. Gerhard Madaus*, a pioneer in the field of phytotherapy, who first discovered and researched the pain-relieving and capacity-enhancing effects of intracutaneous mistletoe injections in osteoarthritis cases. The poplar tree mistletoe extract that he developed under the brand name *Plenosol* is the topic of around 30 publications that document the experiences of thousands of patients. But the "*Viscum album* Monographs" from the specially appointed Commissions C (Anthroposophic Medicine) and D (Homeopathy) in Germany, also cover the administration of mistletoe injections in the case of chronic joint diseases. For these fields of treatment, we also have a wealth of experience. The first randomized trial was conducted with an anthroposophic mistletoe extract from willow trees. It resulted in a significant improvement in symptoms for gonarthrosis patients, comparable to results achieved with the cyclooxygenase inhibitor *diclofenac*, albeit with more long-lasting effects. It is imperative to mention that unlike mistletoe extracts, which are generally well-tolerated by patients, *diclofenac* comes with warnings of substantial risks for the cardiovascular system as well as for gastrointestinal bleeding. Thus it can be said that mistletoe extracts offer a far more favorable benefit-to-risk profile than standard conventional treatments.

Meanwhile, the tried-and-tested product *Plenosol* is no longer available. Extracts derived from apple-tree mistletoe are now the most frequently used option for cases of osteoarthritis. This includes *Helixor® M*, similar in many ways to *Plenosol*.

As I first learned how to inject intracutaneous wheals to treat painful osteoarthritis and spinal syndromes as a young assistant physician from the head physician at my clinic, I was surprised by the quick reaction to the treatment – assuming a correct assessment of the indication, as well as an adequate injection technique and dosage. Later, in my own practice, these early experiences of success were confirmed, except in a few therapy-resistant cases. For many patients, their symptoms even disappeared entirely.

Given this background and these experiences, the present publication takes a long-awaited and crucial step by presenting a thorough introduction to the theory and practice of mistletoe injection therapy for disorders of the locomotor system – embedded in a comprehensive treatment concept based on a holistic, individual view of the patient. My highly esteemed colleague, Dr. med. Kurt Jürgen Zell, to whom I am bound by decades of productive collaboration, deserves our gratitude and appreciation for taking on this task, which has led to such a convincing result. As a physician with a background in orthopedics, chiropractic care, and sports medicine, and a dedicated ambassador for holistic, biological medicine, and owing to his decades of experience with mistletoe injection therapy, he is qualified for this task like no other. I have always learned a great deal from Dr. Zell and owe him many relevant insights, for example, on the use of mistletoe therapy for osteoporosis, an indication for which we have relatively little experience to date.

May this publication find a broad audience and help numerous patients suffering from degenerative joint disorders find what they are searching for: a gentle therapy with few adverse effects and long-lasting results.

Dr. med. Dietrich Schlodder
Anthroposophic Physician (GAÄD), Tübingen

Prologue

"It is no measure of health to be well-adjusted to a profoundly sick society."
Jiddu Krishnamurti

We are living in a highly unusual moment. Never in our recorded history has humankind succeeded in amassing so much information as it has today. Besides books, lectures, films, social networks, and numerous events, our primary portal to that information is the Internet.

For the medical profession, though, this moment should give us pause. We should stop and reflect on what this wealth of information has given us. Do we now have more healthy people and fewer patients to treat? The answer, unfortunately, is a resounding "no." Health and illness figures show that we are spending considerably more money, about five to ten billion euros more each year, for the **healthcare** or **illness industry**. And this despite a global biomedical research budget of 240 billion dollars each year.

No matter how you look at it, everyone involved in or affected by the so-called healthcare industry, from physicians and their staff to pharmacists, nurses, physical therapists, massage therapists, and patients, is, quite plainly, dissatisfied. What is the source of this pervasive dissatisfaction? The answer is relatively simple, as **Prof. Dr. phil. Dr. phil. habil. Dr. med. habil. M.P.H. Paul Ulrich Unschuld** describes in his excellent treatise on commoditized healthcare and what he sees as the "end of classic medicine." Taken together, we arrive at the following diagnosis:

Financial feudalism has overtaken medicine and created a healthcare industry that operates based on a for-profit capitalist logic. Like an avalanche, it brutally levels all that is established and good but that fails to generate a profit.

This conundrum can also be ascribed to the current state of science or, more accurately, to the unidimensional view of most sciences, which operate based on a shallow concept of life and a gross misunderstanding of human existence.

At their core, many of these erroneous perspectives can be traced to the strictly left-brained and mechanistic worldview of health economists and researchers.

Although the basic tenets of this branch of science are already over 300 years old, initially developed by Newton, scientists still cling to them today. In doing so, they forget that science is often based on statistics – a world where the knowing individual does not play a part. Yet science should always be subject to critical questioning. As **Jack Kornfield** writes, it should not be a source of guidance in questions involving ethics, sustainability, empathy, and mindfulness.

We can identify similar phenomena in theistic religions that subscribe to a patriarchal worldview and maintain a strictly male priesthood.

In an enlightened society, it stands to reason that we should have outgrown such outmoded paradigms. **Modern quantum physics** has already given us some promising perspectives. Unfortunately, however, **mainstream science** has failed to take note of such recent developments because the evidence they offer would result in the enormous loss of revenue potential for multiple segments of the growing **illness industry**, especially the increasingly ravenous pharma concerns.

But even if we succeed in unlocking new levels of detail to supplement our current knowledge, this purely mechanical form of science will not help us in our search for greater wisdom. As **Buddha** once said, **when you focus on the details, you often lose sight of the big picture.**

There are few places where this truth can be witnessed so dramatically as in the current state of oncological

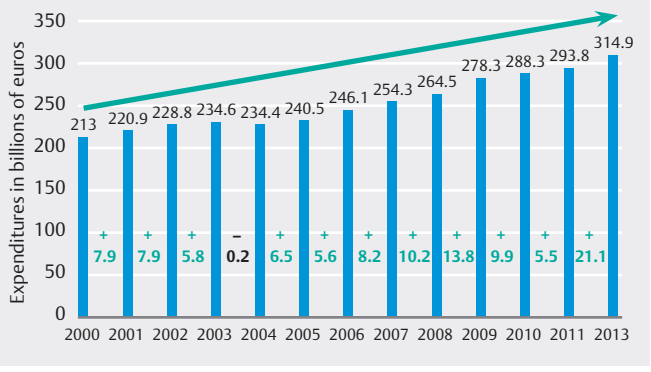

▶ **Fig. 1** Development of healthcare expenditures in the Federal Republic of Germany, 2000–2013 (in billions of euros). © Destatis

therapy. Astronomical figures are spent on finding ever more detailed factors that might trace the exact development of cancer and someday result in a concept for a universal cure. (Modern cancer drugs also come at an outrageous price – a tendency that is reinforced with each new product on the market.)

But the truth is, we will never find such a universal cure. Cells only get sick in a sickened body-mind-soul biological system, one that is merely the reflection of the sickened biological system on our planet. Scientifically speaking, as long as we are no more than animals with an extraordinarily developed left brain, as **Willigis Jäger** writes in his book on the return of mysticism, we will not be able to create a sustainable, forward-looking view of humankind, nature, and medicine.

As a physician with 39 years of practical experience, I am often left incredulous at how conventional scientific medicine succeeds in sealing itself off from clinical experience, operating in the equivalent of a black box.

This black box is, as illustrated above, heavily dominated by special interests in the industry and not interested in any further solutions. In some cases, it is genuinely atrocious to see the extent of suffering created by this medicine. Indicators such as five-year survival rates are used to justify highly destructive procedures that bring severe damage and the loss of quality of life for patients. The entire family ecosystem suffers, often for several years. "Recoveries with defects" (restitutio cum defectum) are not uncommon. And despite enormous research efforts over the past 20 years, we have not been able to achieve a significant improvement in the overall cure rate for cancer.

5 years after the initial diagnosis, 58 % of women and 45 % of men survive their cancer. Often, the result is not healing, but rather infirmity, fear, and suffering!

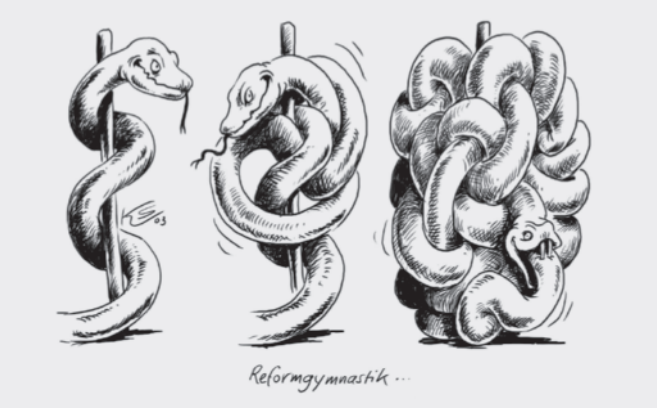

▶ **Fig. 2** "Reform gymnastics". © Klaus Stuttmann

During aggressive chemo- and radiotherapies, which can result in severe damage to healthy tissue, most patients receive neither mistletoe therapy, nor an orthomolecular or oxygen therapy to protect healthy cells. However, in all complementary practices, like my own, these same options have been used with excellent results.

One could speculate that the medical and pharmaceutical industry is intentionally preventing the development of an alternative measure of well-being. A scale that would compete with the five-year survival rate in order to avoid senseless treatments, not only for older patients. But cash flows currently seem to trump patients' interests.

These remarks are not enough to put an end to the madness. Once cancer is diagnosed, we are forced to submit to the current dictatorship of conventional medicine. Statutory health insurance does not cover complementary therapies in Germany; private insurance providers are increasingly scaling back their coverage.

The standard approach: Treat to the bitter end without protecting healthy cells!

Policymakers tend to respond to these numerous complaints and difficulties by introducing legislation for new reforms.

But political bodies rarely have a sufficient number of experienced medical professionals. Policymakers have always claimed to have a bird's eye view, knowing everything better than the people on the ground. The simple rationale: the voters have decided, and we will do their will as we see fit.

Because I have been a practicing physician since 1980, I am intimately acquainted with this development and have been able to follow it for several years. In an openly available article published in 2015 by the German-language medical magazine *Deutsches Ärzteblatt*, it is appalling to read that physicians in Germany currently need to spend 100 days per year on documentation. Nevertheless, in the remaining two-thirds of the year, the medical profession is expected to conduct compassionate, successful, forensically sound and safe medicine. What other profession is able to do the same – or to tolerate these circumstances?

This state of affairs reminds me of the film *Modern Times* by **Charlie Chaplin**. And we are still driven to keep up with the faster and increasingly chaotic pace of capitalism. For my younger colleagues, these devel-

opments might seem like the norm, but I know it differently.

Yes, this is only a booklet about mistletoe therapy and the human locomotor system. But, ultimately, mistletoe is one building block in the renaissance that we so direly need to prevent medicine from devolving into a mechanical undertaking.

At this juncture, I want to recall what it means to be a physician:

Medicine is an art form that avails itself of the tools of science to enable an individual curative treatment!

This process always unfolds between the person in the therapeutic role and the patient. It is a highly individual, two-way process embedded in a relationship at eye level. And mostly successful.

Nonetheless, through the introduction of time limits forced upon us by health insurance companies, what was once an art has meanwhile been degraded to a science. Instead of providing individual solutions, we treat patients based on evidence and in accordance with guidelines. Patients are regarded as uniform, standardized beings. Much like the Volkswagen Golf we bring into the shop: we think that every mechanic has the same spare parts, and every model needs the same inspection, the same fluids, the same tests.

Financial feudalism exacts its most devastating toll when we lose our humility before the big picture, before nature and the value of the unique individual!

And what does it mean to have increasingly fast-paced medicine, oriented more and more on the principle of forensic certainty? An increasingly soulless profession. And the emergence of a new quality of medicine: the age of nocebo treatment. People are under growing pressure as there seems to be less time for medical counseling and practitioners experience growing fears of legal persecution. Meanwhile, a physician faces a malpractice suit every eight years on average, and this tendency is likely to increase.

Financial feudalism results in soulless medicine and nocebo treatments!

Instead of saving money, new costs mount each year as inherently human factors like trust, security, love, and affection lose their place in the system. Medicine is viewed as a simple, mechanistic system of inputs and outputs. Patients frequently seek out new physicians

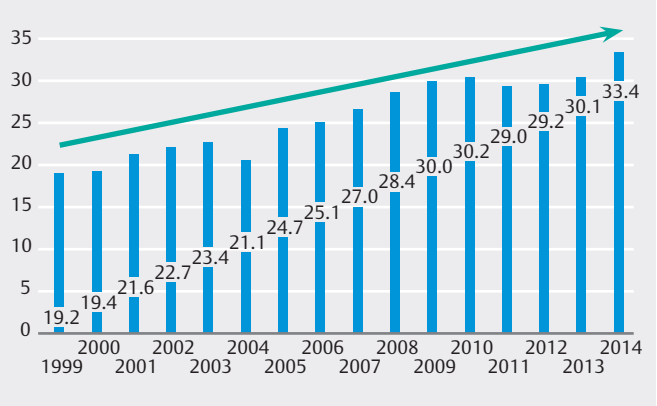

▶ **Fig. 3** Spending on pharmaceutical drugs by statutory health insurance providers in Germany from1999 to 2014 (in billions of euros). © Destatis

and turn to advanced, instrument-based diagnostics as a source of certainty.

Only thanks to the tireless efforts of our colleagues and other dedicated individuals is it possible that our currently imposed medical system is still functional. We are in urgent need of a renaissance in good medicine – and not medicine as a good!

Even though we can already see some light at the end of the tunnel, our society and the actions of our medical profession are still heavily dominated by patriarchal structures. This is apparent in the exploitation of our planet and our biological systems, including humans, and the resulting loss of sustainability. And it is especially evident in our current state of scientific medicine with its left-brained approach. We are living in a permanent struggle (▶ **Fig. 4**).

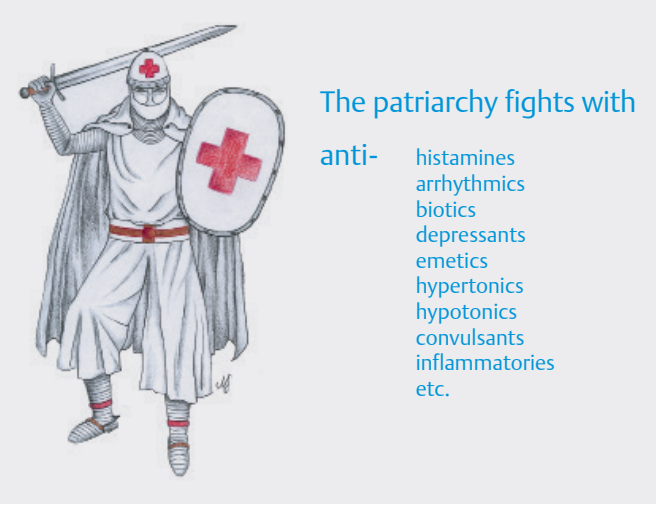

▶ **Fig. 4** Battles of conventional medicine.

What we are missing is a humanistic, holistic view of humankind and the world, like that most impressively laid out by **Rudolf Steiner** in his anthroposophical principles at the beginning of the past century. The major cultures of Europe, Africa, and Asia were also able to establish similar paradigms in the course of their development. Unfortunately, much of that heritage has been lost. While I myself am not an anthroposophist, I did have the good fortune to encounter a number of truths that allowed me to develop a similar view of the world, for which I continue to be thankful today.

Rudolf Steiner introduced the use of mistletoe in oncological therapy as early as 1917. Since then, through their tireless research, small anthroposophical companies have beat the odds (and mainstream science) by improving existing knowledge of how mistletoe from various hosts can be used to treat various cancers.

Thanks to the work of the **Madaus brothers**, in 1934, mistletoe harvested from poplar trees was permitted for the treatment of locomotor system diseases. Its use is truly age-old wisdom. Several therapists and practitioners have since used mistletoe injections to treat disorders of the locomotor system. Thanks to modern, fast-acting antiphlogistics (NSAIDs), yet admittedly drugs with a high potential for adverse effects like ibuprofen or diclofenac, the art of mistletoe injection therapy has been all but forgotten in the last quarter of the previous century. If you are a medical professional, you know who is liable for adverse reactions associated with NSAIDs. In the current medical system, there is never enough time to clarify the entire gamut of patient-specific risks – quite apart from the significant environmental problems caused by the use of these drugs. In India, the use of diclofenac in veterinary medicine (especially in cows) resulted in the death of several millions of vultures due to kidney failure. This, in turn, led to an increase in rabies incidents because other animals such as dogs were infected by feeding off the carcasses. Elaborate measures are now being taken to reintroduce vultures into this ecosystem. And the Indian government has since outlawed the use of the drug in animals.

I have used mistletoe injection therapy to treat diseases of the locomotor system since my first year as a practicing physician in 1980. Much of that knowledge I gained from my chiropractic mentor at the time **Dr. med. Hans Dieter Wolff**, and much of it I was able to develop in collaboration with my brother-in-law **Dr. med Karl-Heinz Teusch** and my former practice partner **Dr. med. Rüdiger Ecker**.

It is with great honor and joy that I contribute to the rebirth of a lost art and share this knowledge about mistletoe therapy with my colleagues.

Introduction to osteoarthritis and spinal degeneration

After seven years of specialized medical training culminating in a residency at the Orthopedic Department of the Saarland University Hospital Homburg, I worked for 14 years as an orthopedist in a joint practice with **Dr. med. Rüdiger Ecker** in Idar-Oberstein, Germany. During this time, I had the opportunity to treat countless patients who helped me gain a great deal of experience in the diagnosis and treatment of degenerative diseases. This experience was immensely valuable to me as I established my practice for biological medicine in Saarbrücken in 2002, and it has been ever since.

Conventional scientific medicine has developed several core tenets related to degenerative diseases of the locomotor system. One critical insight derived from my many years of practice is that many of these tenets do not hold in practical settings. Indeed, they are in need of a revision based on actual clinical experience.

In the boxes to the right, examples of these incorrect and correct tenets are provided in further detail.

TYPICAL STATEMENTS FROM SCIENTIFIC MEDICINE THAT LONG-TERM EXPERIENCE HAS SHOWN TO BE COMPLETELY OR PARTIALLY INCORRECT:

- The radiographic assessment of osteoarthritis is central to the prognosis.
- An MRI or a CT scan is almost always needed for a proper evaluation.
- Osteoarthritis patients frequently need a hip or knee replacement.
- Knee arthroscopy (knee imaging) is almost always required for diagnosis and therapy.
- We have reached the limits of conservative therapy.
- There is nothing more that can be done.
- You will need to go on permanent pain medication.
- You will end up in a wheelchair.

CONTRASTING STATEMENTS BASED ON EXPERIENCE:

- A proper prognosis for osteoarthritis can only be given based on a complete and holistic medical history.
- Only a thorough physical exam will permit an assessment of the current state of a joint – and a competent judgment regarding the required therapy.
- Health problems or complaints often do not correspond with changes shown in a radiographic assessment.
- Once a patient has received a nocebo treatment, that experience is incredibly tough to reverse. Re-establishing trust is essential.
- If a patient has already researched a condition online, then it is often difficult to convince him or her of my conclusions.
- The conservative approach can accomplish more than generally believed.
- Complementary therapies need more time but usually bring good results down the road, as well as long-term savings for the healthcare system.
- Trust is the cornerstone of the doctor-patient relationship. Nothing can replace it.
- You cannot force experience! (Dr. med. Volker Rimkus)
- Belief has the power to move mountains.

Anatomy, function, and metabolism of joints

To gain a better understanding of osteoarthritis, we first need to understand the anatomy, function, and metabolism of joints. That is why I will start with a brief overview of some essential terms and concepts.

Joints consist of two bony elements that move relative to each other in different ways (articulation). For example, the knee joint, where the femur (thigh bone) meets the tibia (shinbone). Sections of the joint that move together are covered by **cartilage** and lined with synovial fluid, which enables the gliding of both elements. The **joint capsule** provides passive support to the joint, while the surrounding muscles play an active role in joint mobilization.

Joint movement happens typically through the exertion of **antagonistic muscle pairs** consisting of an agonist and an antagonist (e. g., the biceps muscle flexes, and the triceps muscle extends the lower arm). This concept of **muscular synergism** is essential for a balanced and sensible approach to muscle building. Both parts of a muscle pair need to be trained and also stretched as required. Their movements are governed by the so-called **peripheral nervous system**, which, unlike the **autonomous nervous system**, we can consciously control. For example, we are capable of deciding whether or not to bend our arm.

Articular cartilage or joint cartilage, which absorbs strain and facilitates movement by gliding, is not maintained by the surrounding bones. Instead, it is fed by nutrients produced by the **synovial membrane**, or the inner lining of the joint capsule, and distributed to the cartilage through **synovial fluid** (also known as **synovia**).

Synovial fluid consists mainly of **hyaluronic acid**. This highly **viscous** substance enables prolonged contact between opposing elements of the joint, ensuring that the cartilage on the articular surfaces can glide smoothly.

Hyaluronic acid also occurs in the formative structure of cartilage (or the **matrix**). Additional components of cartilage include silicon, magnesium, manganese, boron, chondroitin sulfate, methylsulfonylmethane (MSM), and keratin sulfate.

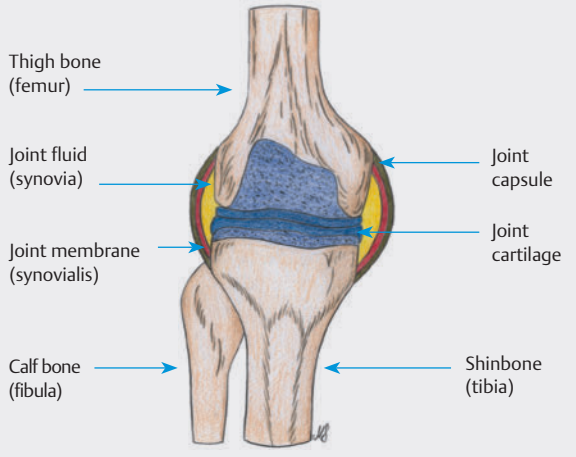

▶ **Fig. 5** Anatomy of a joint.

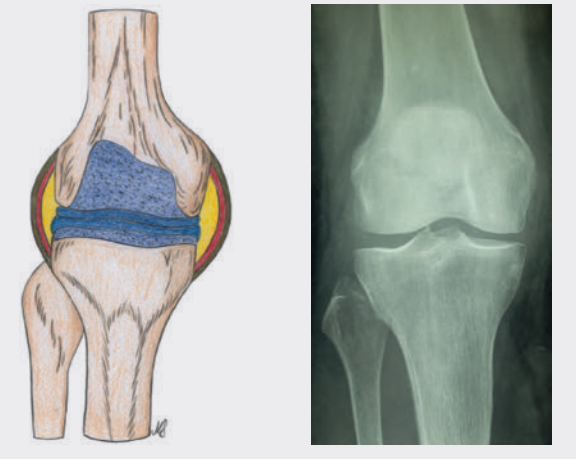

▶ **Fig. 6** X-ray anatomy of a knee joint (cartilage shown in blue, bone in brown, capsule in gray).

Finally, we cannot forget the role of the vascular system in joint health, which ensures the proper supply of oxygen, the delivery of nutrients, and the disposal of waste products.

Only when all relevant components function properly, like the full keyboard of a piano, is it possible to achieve optimal joint function. Healthy joints are maintained by a healthy, organic diet that is free of pollutants! And above all by movement. By strengthening and stretching the muscles and improving stamina!

Radiological anatomy of joints

Although many colleagues will disagree, I still believe that an X-ray is the best method to gain an initial overview of a joint. Just as you would probably not decide to purchase a car after viewing countless images of its layers, so too is the situation with joints. Our first goal is to understand the bigger picture.

Because cartilage, like all other soft tissue, does not have a high radio-opacity, the gap in the joint or joint space is highly indicative of the cartilage situation.

A large joint space does not indicate general cartilage degradation. A narrow joint space indicates general cartilage degradation.

At this juncture, I would like to emphasize that joint X-rays of the lower extremities should always be performed in a normal load-bearing position (e. g., while the patient is standing). Otherwise, the joint space might appear larger than it actually is and thus falsely mimic healthy cartilage. Nearly all radiologists, however, perform X-rays with their patients lying down. Efficacious X-ray requests will be phrased accordingly, for example **left knee anteroposterior (AP) weight-bearing view** or **hip AP erect view**.

Unless more complex deterioration is expected based on the patient's medical history, advanced MRI and CT diagnostics should only be used in therapy-resistant cases. ▶ **Fig. 5** illustrates the anatomy of a knee joint (patella not pictured in the drawing) with a corresponding X-ray image.

The same applies to the anatomy of the hip joint, especially when a diagnosis aims to exclude a deformity such as dysplasia. Radiological imaging should only be performed with the patient in an upright position, as shown in ▶ **Fig. 7**.

The following **case example** illustrates the misunderstandings that can result from wrongly indicated radiological diagnostics.

In summer 2015, a 21-year-old female patient presented with recurring pain in the left groin area, radiating from the groin into the sacroiliac (SI) joint. Regular, mild sport alleviated the pain; however, the improvement remained temporary. The patient was a student in Berlin, and the attending physician ordered an MRI of both hip joints. As is generally known, MRIs are performed in a supine position. The MRI was deemed normal. After a thorough physical exam, no significant findings were revealed. I ordered an upright overview of the hip joint. This image showed insufficient coverage of the femoral head on the left side, at just 85 % (hip dysplasia). This finding led to the hypothesis of intermittent cartilage overloading with reactive synovitis (inflammation of the synovial membrane).

For the spinal column, a similar radiological anatomy applies as for the joints of the extremities, as shown in ▶ **Fig. 8**.

Progression of osteoarthritis

Anatomical osteoarthritis signifies the increasing loss of the cartilage mass of a joint. This process is accompanied by changes in the bony structures beneath the cartilage, and potentially even deformation of the joint.

The deformation of arthritic joints often leads to restricted movement in those joints. As a joint ages and potentially loses its capacity for regeneration, there is also a reduction in its overall performance spectrum. This development is unrelated to symptoms of pain and is mostly a normal part of the aging process in our society.

▶ **Fig. 9** shows both a macroscopic and microscopic view of the increasing loss of cartilage and accompanying bone alterations that occur with the progression of osteoarthritis.

The above description does not apply to **static changes in joints** such as **genu valgum** (so-called knock knees) or **genu varum** (so-called bow legs). These abnormalities result in an unequal distribution of weight or stress so that not all parts of a joint are required to carry the same load. Instead, certain regions of cartilage are subject to greater strain, which makes them wear out more quickly. The situation is comparable to the alignment of a car. If some part of the suspension is improperly aligned, the resulting imbalance can cause uneven wear on the tires and shorten their useful life.

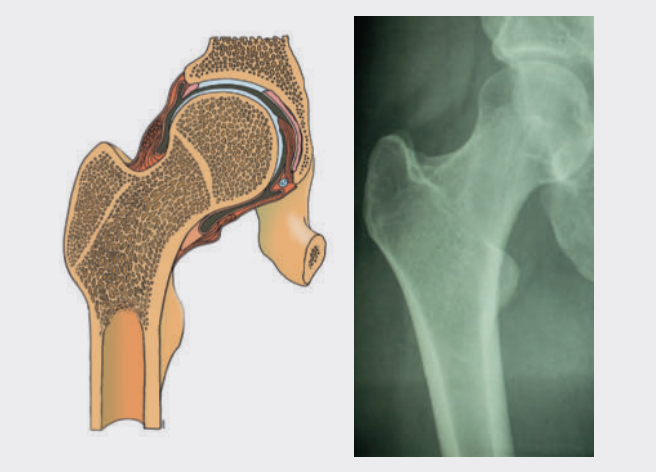

▶ **Fig. 7** X-ray anatomy of a hip joint (cartilage shown in blue, bone in brown, capsule in red).

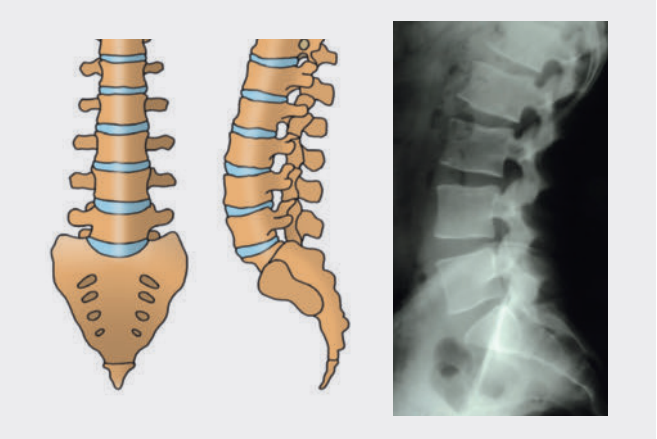

▶ **Fig. 8** X-ray anatomy of the lumbar spine (intervertebral discs in blue, bone in brown).

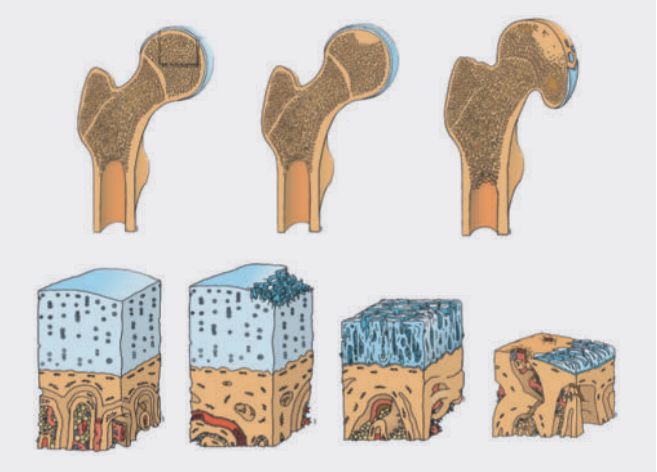

▶ **Fig. 9** Progressive stages of osteoarthritis (cartilage shown in blue, bone in brown, blood vessels in red).

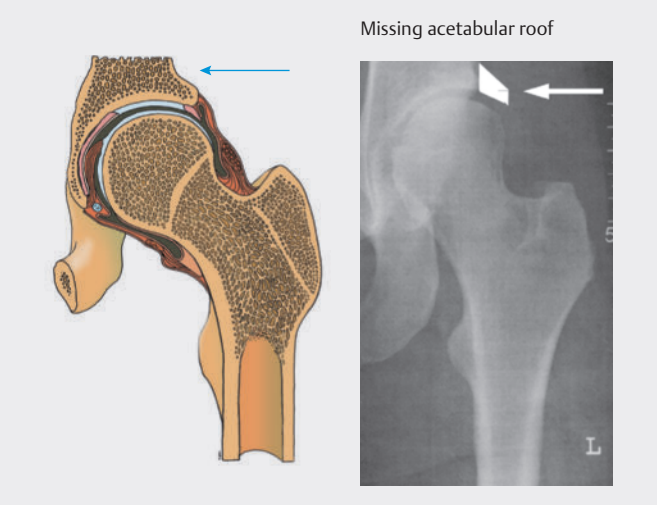

▶ **Fig. 10** Hip dysplasia (cartilage shown in blue, bone in brown, capsule in red).

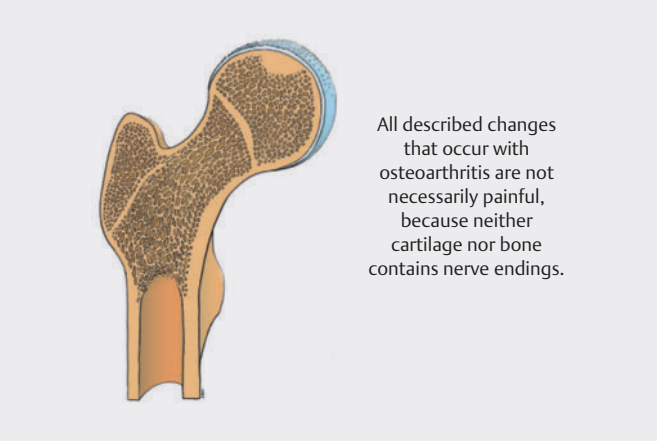

▶ **Fig. 11** Pathological relevance of osteoarthritis.

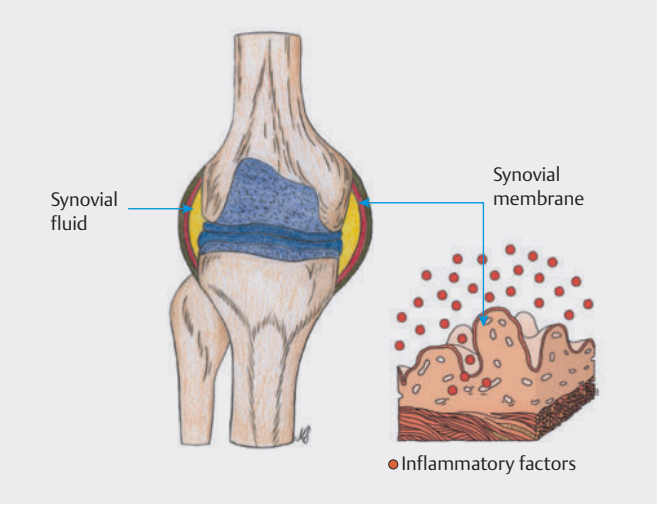

▶ **Fig. 12** An inflamed joint.

In addition to misalignments that occur with growth, there are also congenital abnormalities of the joints or what are known as **dysplasias**. The joints then have pre-programmed biomechanical defects and gradually lose their ability to function correctly with age, especially with sustained stress, since the natural regenerative capacity of the cartilage is exceeded. The result is premature osteoarthritis with frequent pain and irritation. The textbook example is **hip dysplasia**, where the acetabular roof of the socket does not adequately cover the ball portion of the hip joint. This condition often occurs in combination with a large angle where the neck of the femur meets the shaft, a condition known as **coxa valga**.

Practical experience, however, shows that osteoarthritis is not an inevitability in every case of hip dysplasia, provided that the joint is not placed under extreme demands.

▶ **Fig. 10** shows a case of hip dysplasia with inadequate coverage of the femoral head by the acetabular roof, together with coxa valga.

Pathological relevance of osteoarthritis

Taken together, all of the changes described and illustrated for osteoarthritis are not painful per se, because neither bone tissue nor cartilage have nerve endings that can communicate pain. Only when inflammation occurs does an osteoarthritis patient become a rheumatoid arthritis patient, or, in other words, the inactive and non-inflammatory condition becomes active and inflammatory.

In clinical terms, the new situation is similar to a joint inflammation caused by rheumatism (▶ **Fig. 11 and 12**).

The **synovial membrane** (**synovialis**) then produces inflammatory cells (▶ **Fig. 11, 12**) and starts to swell. Unlike cartilage, the synovialis does contain nerve endings, which make this swelling painful. What was initially **latent osteoarthritis** has now become **activated osteoarthritis** (▶ **Fig. 12**).

For decades, numerous textbooks have described the symptoms that result. Depending on the findings and severity of inflammation, they will be more or less pronounced: **inflammation – swelling – pain – joint dysfunction – hyperthermia.**

Articular effusion, that is, an increased formation of fluids in the joint caused by inflammation, is not uncommon in the knee and upper ankle, and seen also in the hip joint.

This symptom may necessitate a surgical puncture of the joint space (arthrocentesis).

Radiographic classification of osteoarthritis

We traditionally classify the progression of osteoarthritis in four stages, which, as already described, do not convey any information about pain symptoms. There is, however, an important addendum to this classification (▶ **Fig. 13**): depending on individual genetics, two very different reaction patterns occur in joints affected by osteoarthritis:

- The **hyperostotic form** of **joint degeneration**, which besides a reduction in cartilage also triggers a significant bone growth response, and, therefore, as the disease progresses, contributes to increasing joint stiffness. Because of the gradual decrease in mobility and quality of life for patients, this condition often leads to the decision for a joint replacement.
- The **hypo-ostotic form** of **joint degeneration**, which results almost exclusively in the loss of cartilage while the patient's mobility remains intact. For patients with this reaction pattern, it is often possible to forgo a joint replacement and opt instead for an excellent course of holistic treatment.

Spinal degeneration

Generally speaking, spinal degeneration is very similar to osteoarthritis of the extremity joints. However, intervertebral disc degeneration (chondrosis or osteochondrosis, depending on the degree of wear) often does not lead to back pain. Complaints linked solely to intervertebral discs are usually characterized by nerve irritation, together with pain or numbness along the nerve path. For example, on the outside or back of the leg. In rare cases, paralysis, as well as weak dorsiflexion or plantarflexion, can be observed in the lower extremities. Irregular intervertebral discs may also result in highly painful irritations of the posterior longitudinal ligament (situated in the vertebral canal and running from the axis to the sacrum).

We commonly summarize these symptoms under the term **sciatica**.

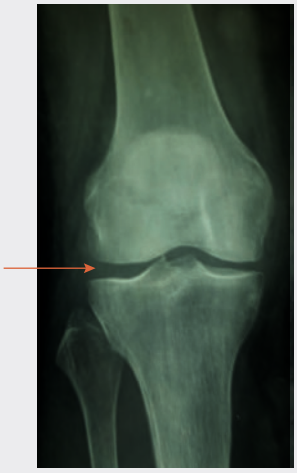

The **joint space** enables an assessment of the

radiographic classification of osteoarthritis

I Joint space loss of 1/4

II Joint space loss of 2/4

III Joint space loss of 3/4

IV Complete loss of joint space

▶ **Fig. 13** Radiographic classification of osteoarthritis.

Similar complaints can be observed with nerve irritations caused by intervertebral disc disorders of the upper extremities, which are referred to as **brachialgia** or **cervicobrachial syndrome** (▶ **Fig. 14**).

In my experience, no more than 10 to 15 % of spinal pain results from damage to intervertebral discs. The remaining portion stems from muscular disorders, ligament and tendon problems, and especially osteoarthritis of the vertebral joints. Indeed, these disorders are typical occurrences within an aging Western society.

All along the spinal column, vertebral joints and costovertebral joints tend to get "stuck." This fact has been instrumental in the development of **chiropractic therapy (manual therapy)**.

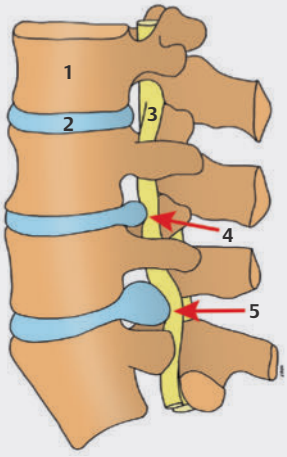

1 Vertebra

2 Disc

3 Nerve

4 Slipped disc (minor)

5 Slipped disc (severe)

▶ **Fig. 14** Slipped spinal discs (discs shown in blue, bone in brown).

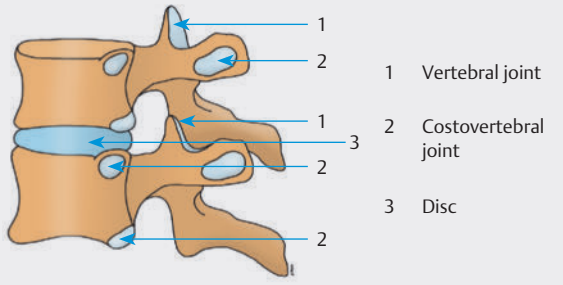

▶ **Fig. 15** Joints along the spinal column (disc shown in blue, bone in brown).

In recent decades, we have witnessed the emergence of techniques such as **fascia therapy**, **osteopathy**, and **craniosacral therapy**, which integrate fascia, muscles, and even internal organs.

Vertebral joints have a special significance when it comes to spinal degeneration. Osteoarthritis in these joints often leads to chronic symptoms – which happens to be an ideal field for mistletoe therapy. Irritations to spinal ligaments frequently result in painful symptoms as well. Imaging procedures such as MRIs and CT scans primarily reveal disc degeneration, a protrusion, or a slipped disc. But the majority of these degenerative changes are not clinically significant. Only a thorough clinical exam can provide actionable results in these cases; otherwise, the standard imaging procedures mentioned above are frequently misleading.

Active and inactive osteoarthritis

This distinction is crucial to a patient's current prognosis for osteoarthritis treatment. Initially, I explained that medicine is an art form that draws on scientific findings and research. The most vital component for this prognosis is adequate practical experience in assessing the condition of a joint. Before an exam, precise and specific questions are generally a useful tool.

If the patient reports increased pain with movement and physical stress, this indicates an active form of osteoarthritis.

If the patient reports an improvement with increased movement and physical stress, the osteoarthritis is most likely inactive.

Unfortunately, many patients literally try to "run away" from the pain, but end up placing more and more stress on the joint. This reaction tends to be commonplace; I have experienced it on several occasions. If an active form of osteoarthritis is present, and the patient tries to treat it with an excessive amount of movement, this can harm their prognosis.

Conversely, some patients will tend to rest even though their osteoarthritis is inactive. This response also makes their prognosis less favorable, as they start to lack the muscular strength for adequate joint mobilization.

Holistic aspects in the treatment of osteoarthritis

Conventional scientific medicine has doubtlessly achieved positive results in the treatment of osteoarthritis and spinal degeneration. Promising approaches in this area rely on targeted improvements in muscle strength and, thus, in overall joint stability. The profession of physiotherapy came into being as a result of these labors.

Thanks to an increasingly effective range of techniques, it is safe to say that we have achieved a sound, evidence-based standard. Meanwhile, we even have highly advanced massage techniques that can help a large number of patients.

Together with the tried-and-tested method of electrotherapy, both physiotherapy and massage belong to the basic components of a successful conservative approach to osteoarthritis and spinal degeneration. And, lest we forget, such an approach also includes the entire spectrum of biomechanics and orthopedic measures. The indisputable success of these methods is also why they are not the subject matter of this booklet. I am extremely grateful to have enjoyed an in-depth education and training in orthopedics that gives me the grasp of the locomotor system that I have today. Indeed, a sound understanding of biomechanics is the foundation for every successful orthopedic therapy.

As early as 1741, the Paris-based pediatrician **Nicolas Andry de Boisregard** compared the orthopedic profession with that of a gardener who places his hand on a crooked young tree to correct its growth. And so, the symbol of orthopedics was born (▶ **Fig. 16**).

▶ **Fig. 16** Symbol of orthopedics: the "tree of Andry."

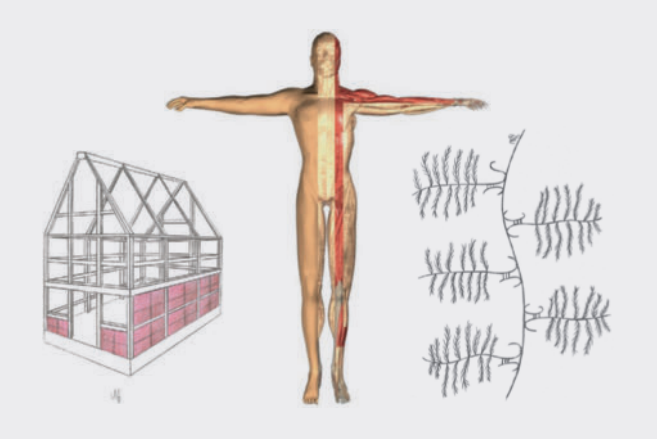

▶ **Fig. 17** The connective tissue matrix.

Osteoarthritis and spinal degeneration from a connective tissue perspective

The **connective tissue matrix** represents the fundamental starting point for nearly every complementary treatment method. Given that significance, I would like to provide a brief overview of its function. This knowledge is both essential and extremely valuable for the successful treatment of osteoarthritis (▶ **Fig. 17**). Unlike a jellyfish, which only retains its shape under water pressure and immediately collapses when removed from its element, mammals like humans possess an internal "scaffolding" that is responsible for the form and structure of our species: that scaffolding is our connective tissue. Like a half-timbered house which contains blocks or stones between its beams (▶ **Fig. 17**), this three-dimensional framework also contains cells embedded in its structures. Yet no vessel has a direct connection to any of those cells. All nutrients (e. g., vitamins) that need to reach the cells must first travel through the connective tissue. Moreover, all cellular products (e. g., hormones) distributed to the bloodstream also need to move through the **matrix**. This vast framework is akin to a **distribution**

hub of an enormous and marvelous biochemical factory. The **vascular system** (arteries and veins) provides the **supply and disposal channels** for the **manufacturing plants we call "cells"**. Different cellular products and waste move through the matrix. The comparison with a modern factory system is truly fitting.

The Austrian physician **Dr. Alfred Pischinger** was the first to describe the concept of the body's system of **ground regulation** while providing convincing evidence of the central role of the connective tissue in its processes. Pischinger's discovery of the connective tissue space has since come to be called the **extracellular matrix**. His 1975 book on the "system of ground regulation" is a standard reference for therapists who follow a matrix-based approach (▶ **Fig. 18**). **Prof. Dr. med. Hartmut Heine**, anatomist and biologist, spent his entire life researching the properties of the extracellular matrix and its fundamental regulatory function. He, too, provided us with pioneering publications in this field.

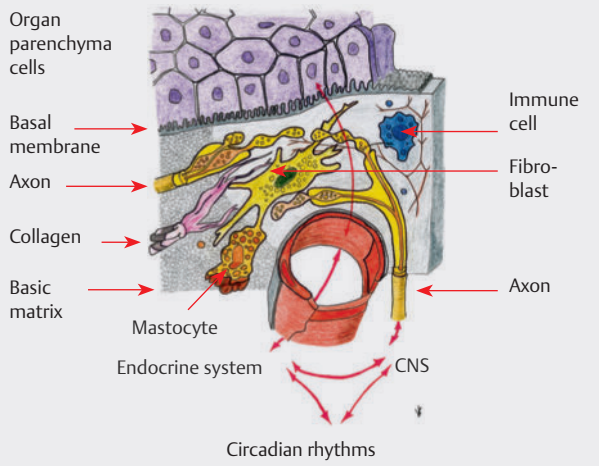

▶ **Fig. 18** The connective tissue matrix, according to Prof. Dr. med. Hartmut Heine.

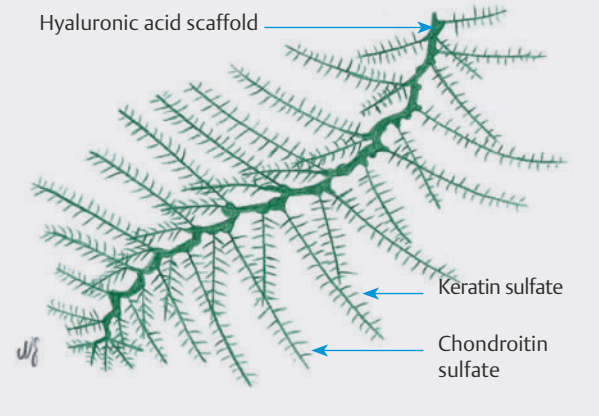

▶ **Fig. 19** Brush-like matrix structures.

This matrix is where we find the fibers of the autonomous nervous system, the lymph vessels, and the white blood cells that form the body's first line of defense against invading viruses and bacteria. It contains incoming connections to the autonomous nervous system and the endocrine system, which controls the body's hormone pathways. The regulation of acid-base levels, electrolytes, and oxygen levels all happens in this space. The interlinking of these regulatory systems results in a **biorhythmic order**, which is increasingly being jeopardized by various lifestyle factors.

For our present purposes, this connective tissue framework is vital because it represents a highly dynamic system that is continuously under construction. The **fibrocyte** is the crucial cell that is responsible for building the fibrous structures of our connective tissue. **Continuous construction (by fibrocytes) and deconstruction (by macrophages) help maintain the matrix in a state of equilibrium**.

The entire matrix structure consists of sugar and sugar-protein macromolecules **(glycoproteins)** penetrated by a network of collagens and elastic fibers. In particular, the matrix possesses a high water binding capacity and the ability to exchange ions.

The brush-like structures of the matrix allow this system to act as a giant molecular filter that picks up and screens nearly everything in the body and before allowing it to pass. When carbohydrates or animal protein are not consumed in moderation (otherwise known as "overeating"), the matrix responds with an increased production of collagen and glycoproteins, which are then stored in the matrix.

These molecular deposits gradually begin to block important transit pathways to cells residing in the matrix (▶ **Fig. 19**).

Similarly, the stressors of our modern lifestyle and diet, laden with additives and toxins that are wholly foreign to the human constitution, slowly but surely clog this molecular filter, robbing the underlying cells of valuable vitamins and nutrients. In his book on protein storage diseases first published in 1984, **Prof. Dr. Lothar Wendt** pointed out the relationship between excessive protein consumption and the chronic diseases of modern society. Especially animal proteins such as milk products and meats result in detrimental changes to the matrix structure due to large protein

SOME BASIC PRINCIPLES OF MATRIX MEDICINE

- A matrix-based approach is particularly beneficial to patients with chronic osteoarthritis symptoms that cannot be traced to muscular weakness.
- Cartilage has a better chance of healing in an alkaline milieu, yet most patients suffer from hyperacidity.
- Patients should try to drink at least 30 ml per kilogram of body weight per day to ensure that the matrix is adequately flushed out with fluids.
- A full blood count (mineral levels including reserves) should be taken prior to a long-term regimen of alkaline supplements. However, it is not necessarily required for short-term regimens of four to six weeks.
- Alkaline powders with a low mineral content, such as Alkala N, are suitable for treatment.
- For overweight patients, an alkaline diet and resulting weight loss will improve matrix function and decrease stress on the joints and the spine.
- Following a diet that is low in animal protein for four to six weeks will support matrix recovery and regeneration.
- In the medium to long term, patients should adopt a diet that is low in animal protein and rich in vegetables.
- Specially formulated homeopathic complexes promote the natural detox function of the liver, kidneys, and lymphatic system.
- Alkaline herbal teas, fresh vegetable juices, and green smoothies support the removal of toxins.
- High-quality salts such as rock salt or Himalaya salts provide valuable trace elements.
- Alkaline baths, saunas, infrared cabins, and sports offer further options to decrease acidity.

stores. The body's connective tissue becomes overly acidic and clogged by protein deposits and waste products. Immoderate protein consumption is the source of **hyperacidity** and the starting point for **deacidification therapies**.

Regarding the density of the matrix, and therefore its relative permeability to various substances, a basic distinction is made between two states existing along a continuum: the first, the **sol state**, can be described as highly permeable (from sol = solution), and the second, the gelatinous **gel state**, is significantly less permeable to various substances. The fluid balance in the body is a significant factor that determines matrix permeability.

A healthy body requires 30 ml of water for every kilogram of body weight to ensure a proper filtering function of the matrix (i. e., someone weighing 50 kg, should drink 1.5 liters of quality water daily.)

Naturally, the biological and biochemical function of the matrix as a whole is far more complicated than can be described here.

There are many ways to arrive at a correct hyperacidity diagnosis. These include a patient's medical history, a physical exam, segmentary electrography or decoder dermography, a full blood count, global diagnostics, bio-electronic terrain analysis based on the work of Vincent or simply a urine test for acidity, to name a few.

As we will see later, mistletoe extract acts directly on the matrix of the dermatome (i. e., through a dermal or skin reaction) and leads, through various regulatory circuits, to reactions in the cartilage matrix with a significant regenerative effect.

Osteoarthritis and spinal degeneration from a metabolic perspective

Human **cell metabolism** has several similarities with a giant biochemical power plant. Imagine that in each cell, about 30,000–100,000 metabolic reactions are happening every second. If we multiply this number by the number of cells in the human body – approximately 20 trillion cells – we can only marvel at this impressive facility (▶ **Fig. 20**).

Inside the cell, the **mitochondria** are the power generators that produce **energy in the form of ATP** (adenosine triphosphate). Originally free-living bacteria, mitochondria entered the cell in the process of evolution (and their bacteria-like outer membrane still makes mitochondria highly susceptible to antibiotics and pesticides). On average, an individual cell contains about 1500 mitochondria.

For heart and brain cells, that number rises to 4500; for egg cells, it is 100,000. Humans generally produce their body weight in ATP every day. That production is adjusted based on varying energy requirements. Athletes and people whose jobs demand heavy manual labor require more ATP than people with desk jobs.

Like a car used only for light errands and driven on city streets, we do not usually tap into our maximum physical capacity. Similarly, if some of our mitochon-

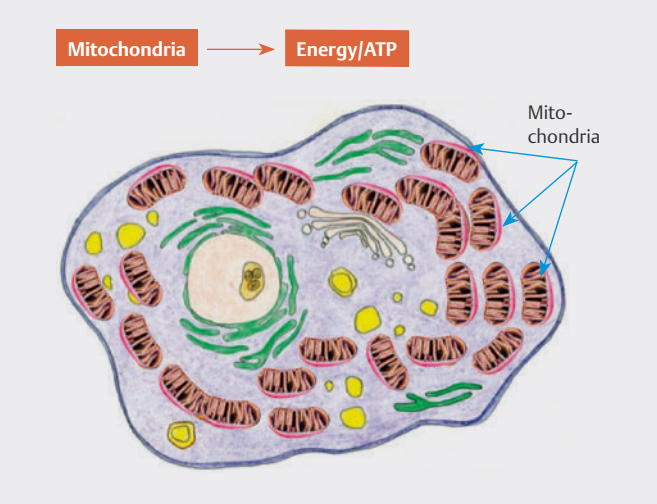

▶ **Fig. 20** Cell with mitochondria.

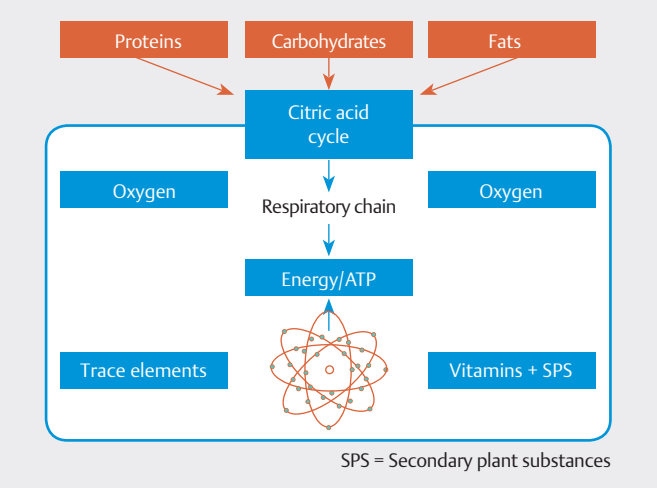

▶ **Fig. 21** Micronutrient synergy and ATP production.

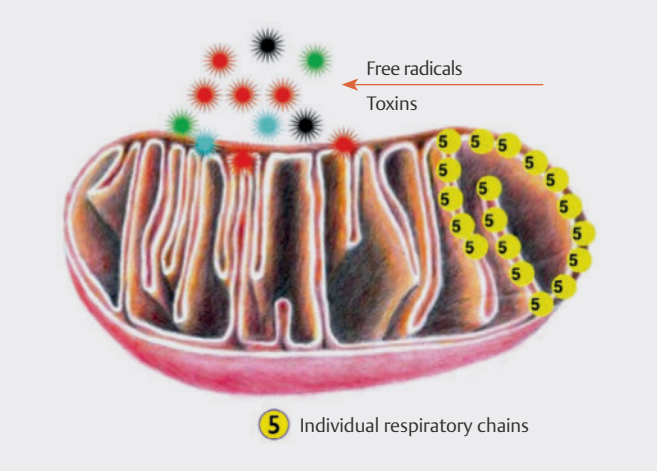

▶ **Fig. 22** Mitochondrion with respiratory chains.

dria cannot contribute to our daily energy production, their failure might go unnoticed – or mostly unnoticed – in the course of our everyday activities.

Chronic diseases only become obvious when more than 60 % of mitochondria are damaged.

In the following, I will use a simplified model of the processes inside a cell. ATP is produced through a complex biochemical process known as the **respiratory chain**. Looking at this vital process, our inherent need for a **healthy planet as our natural biotype** becomes increasingly evident. Healthy cell metabolism depends heavily on natural substances. In addition to minerals and trace elements, those substances include vitamins, secondary plant substances or phytochemicals, proteins, sugars, and fats – all in a proper balance.

During the **five steps of the respiratory chain**, we also need **free electrons**, which we can only get from fresh foods. If we picture the current **state of nutrition in modern societies**, it should immediately be clear that our levels of ATP are likely to fall from year to year. Our mitochondria may also cease to function due to our current environmental situation. The inner membranes of mitochondria where ATP production occurs consist primarily of **phospholipids** (phosphatide and fatty acid molecules) arranged in folded accordion-like structures containing numerous (five-step) respiratory chains (▶ **Fig. 22**).

Metabolic disorders in the mitochondria generally develop in one of three ways. First, a diet that is overly rich in carbohydrates or proteins will cause the matrix to grow denser and eventually clogged (the gel state), making it difficult for nutrients and oxygen to pass through the matrix to the cells and reducing the nutrient supply to the mitochondria. Second, a diet that is generally low in nutrients (as is the case with ultra-processed industrial foods) will also inhibit the function of the respiratory chain (▶ **Fig. 21**). Third and most of all, the presence of foreign substances can fully or completely inhibit mitochondrial function. Such elements include metals such as aluminum, mercury, lead, nickel, cadmium, strontium, and tin.

Free radicals (NO and O radicals) can also be damaging to membranes.

Several different poisonous chemical substances that we unknowingly absorb through food, clothing, cosmetics, dental fillings, and our environment may also have a detrimental effect. Indoor toxins (in paints, flooring, walls, and insulation materials), and

especially cleaning agents, can be highly toxic to mitochondria.

Many prescribed medications can aggravate the situation even further, since mitochondrial medicine, like matrix-based therapies, still has not entered the black box of mainstream science.

This multifactorial damage results in a more or less pronounced form of mitochondriopathy (or mitochondrial disease) and potentially the demise of entire organ structures. Depending on individual genetic patterns, this degeneration then manifests in modern diseases such as osteoarthritis. As with the matrix-based perspective, we can once again recognize a universal mechanism of modern-day disease: the failure to honor requirements that emerged in the course of our evolution and became anchored in our genetic code. Necessities such as proper nutrition and adequate exercise as well as rest (▶ **Fig. 23**). **Cell symbiosis therapy**, as described by **Dr. med. Heinrich Kremer** and **mitochondrial medicine** by **Dr. Franz Enzmann** provide two outstanding, evidence-based approaches for those interested in learning more about these topics.

When **mitochondriopathies** are present, the oxygen-processing capability that the mitochondria gained during the last ice age starts to decrease. With time, cellular respiration as a form of energy production is no longer possible. The cell gradually converts to a different metabolic pathway developed before the last ice age, which is the **anaerobic digestion of (blood) sugar in the cytosol** (intracellular fluid). This early form of biochemical energy production that is still available to our cells provides 16 times less energy than aerobic digestion.

With this shift in metabolic pathways, energy production in the cells gradually becomes slower and slower. As a by-product of anaerobic digestion, **lactic acid (lactate)** is released into the matrix by the cell, adding another source of acidity to the body. This process will be familiar to anyone who has ever experienced muscle soreness. When mitochondria are not able to function properly due to a lapse in training, poor condition, or a lack of proper nutrients, muscle cells initiate an anaerobic glycolysis process and pump the resulting lactic acid into the matrix, which then leads to typical complaints of pain and stiffness in the affected muscle regions. This observation, however, contradicts the widespread scientific claim that attributes muscle soreness to micro-tears in muscle fibers.

The drawings in the following (▶ **Fig. 24–26**) show how the increasing loss of mitochondrial function finally leads to the cessation of aerobic respiration, resulting in glycolysis and the production of lactic acid.

Incidentally, I would like to note that during mitosis (cell division), every cell temporarily turns to anaerobic glycolysis and produces its energy outside of the mitochondria. Here we have identified a crucial juncture for the potential development of cancer in the presence of mitochondriopathy.

Glycolysis plays into the basic division of cells. The lactic acid from this process is pumped out of the cell and forms a mantle around the sick (potentially can-

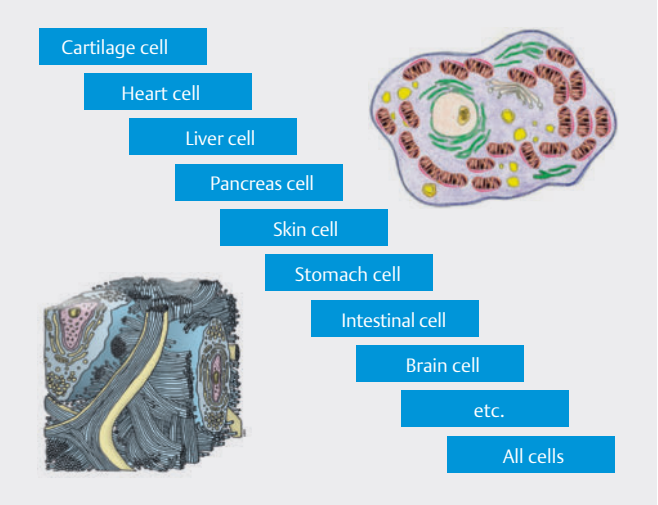

▶ **Fig. 23** Mitochondria are present in all types of cells.

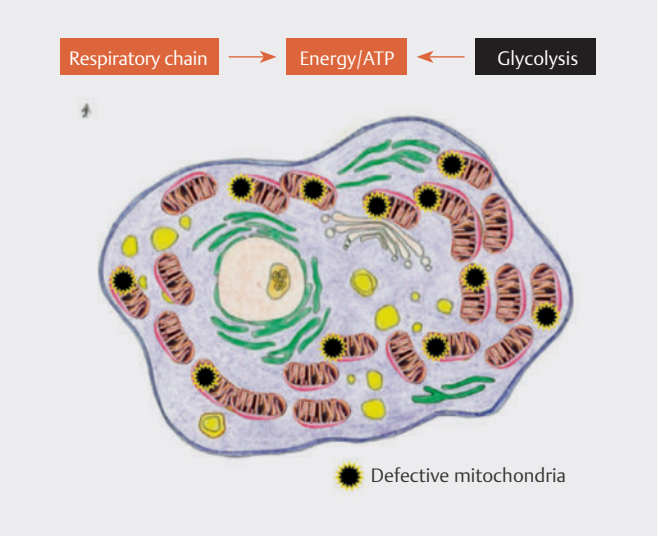

▶ **Fig. 24** The gradually loss of a respiratory chain.

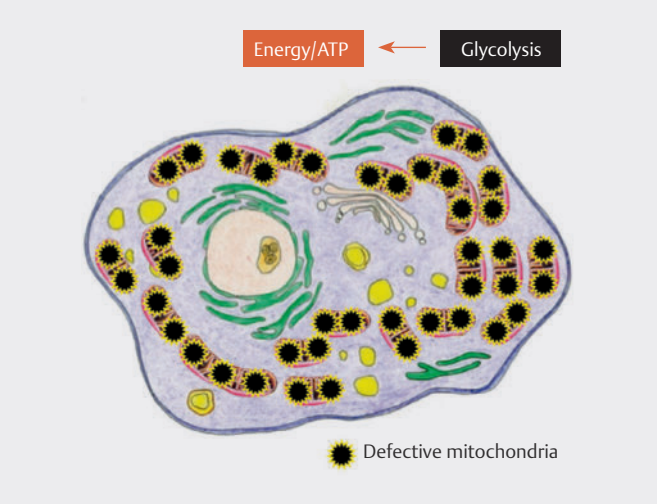

▶ **Fig. 25** Total loss of a respiratory chain.

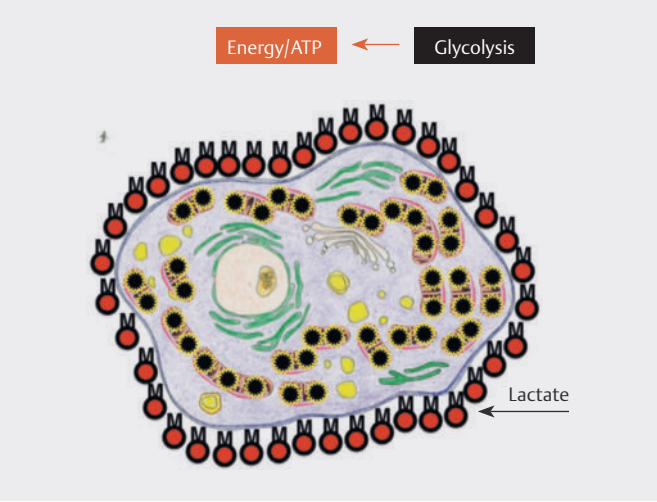

▶ **Fig. 26** Lactic acid (lactate) outside the cell.

cerous) cell. This mantle interferes with conventional therapies (e. g., chemotherapy) and inhibits the ability of the immune system's natural killer cells to eliminate tumor cells.

Numerous tests are available to diagnose a mitochondrial disease. For example, it is possible to measure ATP levels in the blood or of lactate dehydrogenase, the enzyme that breaks down lactic acid.

Because mistletoe therapy is capable of initiating the production of elastic fibers by chondrocytes (cartilage-building cells), it can also be assumed that this form of treatment also has a positive effect on mitochondrial metabolism.

Osteoarthritis and spinal degeneration from the autonomous nervous system (ANS) perspective

Since the early 2000s, I have begun to take a more in-depth look at the underlying causes of disease. I attended several seminars with **Dr. med. Thomas Rau**, chief physician at the Paracelsus Clinic near St. Gallen, Switzerland, whose books, classes and publications are nothing short of groundbreaking for the field of biological medicine.

His work has helped me rediscover the importance of metabolic processes and the autonomous nervous system (ANS) for my own diagnostic and therapeutic approach – while also showing me a wealth of useful knowledge and information.

Regulation instead of attack was the topic of the 49th Medizinische Woche held in Baden-Baden, Germany. Indeed, it is astonishing and incredible how the body regulates and organizes the 20 trillion cells in its organ system to keep that vast biochemical factory and its governing character in such perfect working order.

Here we can take a moment to reflect on what life is about – the capacity for self-regulation and repair!

The human body as a biological system is extremely resilient and capable of healing most anything, as I have witnessed many times.

As a highly dynamic, complex information-processing and open biological system, the human body possesses an inherent capacity for regeneration.

Regulatory mechanisms in the human body show a decreasing material density as we move up through the hierarchy into the immaterial, mental, and creative layers.

- Hormones
- Vegetative nerves
- Peripheral nerves
- Brain
- Meridian system
- Mind and will
- The creative principle

Back as a young, nervous student I was already able to experience the effects of a dysregulated ANS through disruptions such as heart palpitations, tremors and shaking, sleep disorders, and the like. Though my physicians at the time were somewhat overwhelmed by my long list of symptoms, they succeeded in locating the

SOME BASIC PRINCIPLES OF MITOCHONDRIAL MEDICINE

- Alongside the matrix, mitochondria represent the universal key to modern diseases.
- Particularly patients with complaints in several different organ systems are likely to be suffering from mitochondrial disease.
- The best protection for mitochondria is an organic diet free of pollutants and with a moderate caloric (energy) content.
- Nutritional supplements with natural, non-modified substances and vitamins such as vitamin B, trace elements, resveratrol, turmeric, ginseng significantly enhance mitochondrial function.
- Basic multivitamins (or nutritional supplements that cover daily requirements) have been shown to have a positive effect.
- Always ensure that compounds are of superior quality and free of additives.
- One day of fasting per week or month has a highly regenerative impact on mitochondrial function.
- Regular sport activities at a light to moderate level help improve mitochondrial function in the long term.
- Stress causes densification of the matrix (the gel state), a change which is triggered by the ANS and results in a reduced nutrient supply to the mitochondria. Therapies such as acupuncture, autogenic training, meditation, order therapy, etc. can be helpful in this case.
- If resistance to therapy is observed, it is usually due to excessive stress or toxins affecting the mitochondria. Urine should be tested for toxic metals, e. g., after a DMPS injection or infusion.
- Matrix alterations and mitochondriopathies often present together; a poorly functioning matrix must be treated in combination with mitochondrial deficiencies.

source of my problems and helped me with a few simple remedies. The autonomous nervous system regulates all inner organs and metabolic functions. It cannot be directly influenced by our will. Only through autogenic training, and later meditation, was I able to achieve a certain amount of control over my symptoms. Today, after years of practice, it is possible for me to intervene and have a positive impact on disease, both when it starts and as it progresses. The human mind and will are not the subject matter of this booklet. However, they do represent the high road when it comes to positive solutions – not only in the treatment of disease.

The functioning of the autonomous nervous system is similar to a modern computer. Two nervous systems (**sympathetic** and **parasympathetic nervous systems**) are directly wired to various centers of the brain (**hypothalamus** and **brain stem**), supplying the smooth muscles, blood vessels, internal organs, and glands. These two systems exist in a mostly antagonistic relationship, that is, one system might trigger a reaction at a given site, while the other inhibits it. All external and internal influences affecting our biological system are controlled and regulated by this mechanism. As the body temperature rises, sweat is secreted; physical activity triggers an increase in blood pressure. This dual system is designed to maintain equilibrium so that neither side gets the upper hand. However, factors like sustained stress can lead to an increased heart rate (tachycardia) that can no longer be regulated on its own. In cases of emotional trauma or psychological disorders, we can find multiple organ disorders which in traditional device-based diagnostics may not indicate a disease per se, but which can

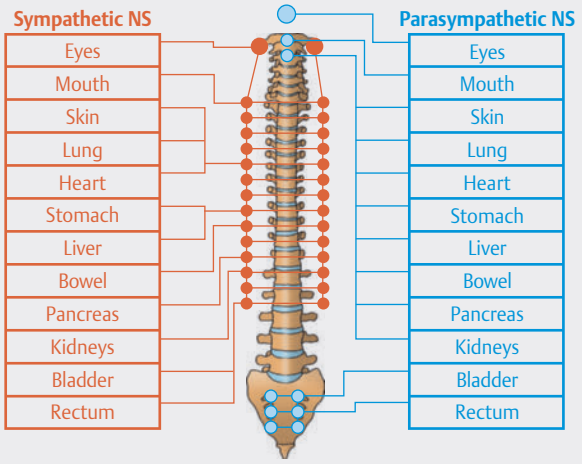

▶ **Fig. 27** Schematic diagram of the ANS.

still be agonizing for patients: heart trouble, digestion problems, renal dysfunction, back pain, etc. If these symptoms persist, they often develop into clinically diagnosable diseases such as ulcers, high blood pressure, diabetes, osteoarthritis, etc.

Once again, we can see the direct link to our emotional situation and with it to our mental and spiritual state. In such cases, it is genuinely a high art for the medical practitioner to attribute symptoms correctly without recurring to daunting and expensive diagnostic equipment. Besides empathy, this process also takes time, which has been strictly limited by health insurance companies. Most of all, regular patient check-ups are necessary.

Mineral or hormone deficiencies can, under certain circumstances, give rise to similar symptoms. And this can impact negatively on our mental and spiritual state. So we enter a constant feedback loop, where both causes trigger each other, resulting in a painful downward spiral of disease.

But first, let us return to take a closer look at the basic principles of this system.

By night, the body replenishes its energy reserves (anabolic synthesis metabolism/anabolism). By day, this energy is consumed (catabolic energy metabolism/catabolism). In other words, anabolic activity builds up the body while catabolic activity tears it down, in a constant cycle.

For those who are familiar with cell anatomy, I will point out that energy reserves can – and must – also be replenished by day in the cytosol (intracellular fluid); otherwise, sustained physical performance like riding in the Tour de France would not be possible. All metabolic functions occur as a constant give and take, which the Chinese defined as **yin and yang**. The autonomous nervous system must maintain balance and above all, its ability to react (▶ **Fig. 28**).

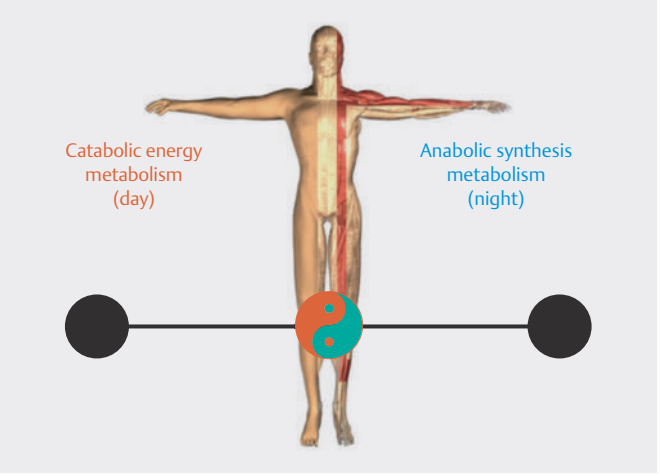

▶ **Fig. 28** Function of the metabolic system.

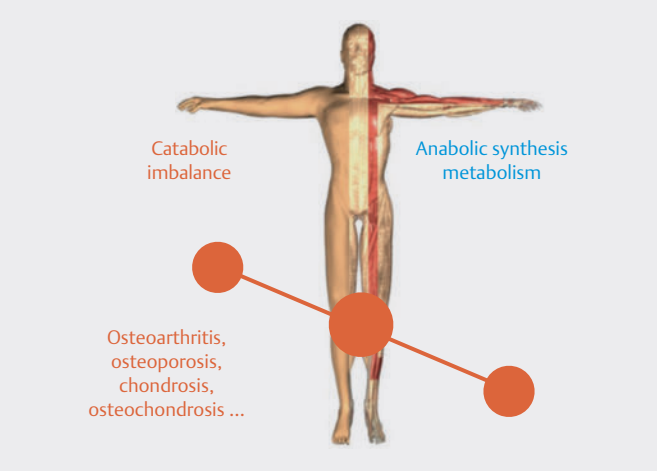

▶ **Fig. 29** Function of the metabolic system.

As described in the previous chapter, one result of cellular metabolism is energy production. The ANS governs this process. If the ANS is unable to maintain a balance and starts to tip in one direction, with too much anabolic (constructive) or catabolic (destructive) activity, the result can be (chronic) disease. As **Dr. med. Bodo Köhler** has written on the subject of metabolism and nutrition, 80 % of chronic diseases are characterized by a catabolic state (▶ **Fig. 29**).

There are diseases marked by overactive anabolic pathways and expressed in acute inflammation, such as rheumatism, allergies, and certain forms of blood cancer. While such disorders are not the main emphasis of this booklet, it does bear mentioning that catabolic diseases can suddenly cross over to become anabolic diseases, and vice versa.

Degenerative, catabolically triggered forms of osteoarthritis can under certain circumstances derail into an acute (anabolic) situation that requires entirely different acute care (cooling, anti-inflammatories, and even immobilization). Metabolism and autonomous regulation by the associated nerve structures are not seldom influenced by mineral and even hormonal imbalances. Here, too, it is essential to ensure **correct natural nutrition** derived from our **earthly biotope** in the proper proportions to reflect our **human biotope**. Nutritional health enables the optimal function of the autonomous nervous system and well-functioning cellular metabolism.

Potassium and magnesium are beneficial to anabolic pathways. They can also be used therapeutically to support recovery. Conversely, sodium and calcium support catabolic activity. An (acute) allergy triggered by an anabolic shift, for example, can be treated with calcium.

Without a doubt, our varying emotional states have the most impressive effect on our autonomous nervous system.

Our modern society, defined in many areas by fast-paced, high-pressure, competitive behavior, and power struggles, is a breeding ground for catabolic disorders.

SOME BASIC PRINCIPLES OF METABOLISM AND THE ANS

- Both emotional and mental states, as well as changes in body chemistry, can have acute or long-term effects on the ANS and metabolic activity.
- Degeneration of the locomotor system is usually triggered by a chronic catabolic state and may require a multi-pronged anabolic treatment.
- Minerals such as magnesium and potassium, along with high-quality anabolic proteins, can support such an approach.
- Hormone therapies using anabolic bioidentical hormones (e. g., following Dr. med. Volker Rimkus) can have a highly beneficial effect.
- Chronic disorders are often marked by a non-adaptive or poorly adaptive metabolism. Their root cause is often located in the intracellular matrix as the body's primary biochemical distribution hub.
- All of the resources provided by order therapy should be considered. Rhythm is health.
- Natural rhythms of exertion and rest (yin and yang) must be relearned.
- A healthy attitude that combines a strong emotional and intellectual balance with spirituality is a potent recipe for success.

Not everyone is susceptible to this tendency. Non-emotional types will often remain unperturbed. More emotional people will, in extreme cases, register every emotional situation physically. Getting caught up for too long in one-sided emotions or emotional roller-coasters can cause disease. The discipline of psychology has already provided ample evidence of this insight.

For those who have read attentively so far, it should become increasingly clear that good medicine requires so much more than a handful of prescriptions or manifold diagnostic devices.

The classic modern ailments affecting the locomotor system are triggered by a chronic catabolic imbalance and they are exemplary in this regard.

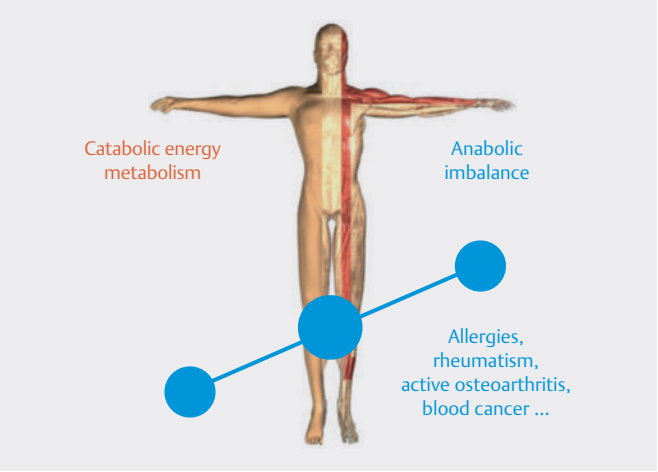

▶ **Fig. 30** Function of the metabolic system.

This situation is exacerbated by aging and associated maldigestion.

As common catabolic diseases, osteoarthritis, spinal disorders, and osteoporosis respond well to mistletoe therapy because of the anabolic and highly regenerative properties of mistletoe.

Osteoarthritis and spinal degeneration from a meridian systems perspective

In 1992, five years after establishing my orthopedic practice, the limits of conventional medicine were becoming increasingly apparent.

I began searching for new ways to expand my therapeutic and diagnostic expertise. My first stops along that journey were homeopathy, Bach flower therapy, and various nutritional concepts. While it was helpful to learn about these topics, I soon realized that my finite brain did not have enough capacity for the infinite wisdom of homeopathy. Luckily, it was around that time that I attended an introductory seminar on acupuncture led by **Dr. med. Jochen Gleditsch**, who demonstrated some impressive clinical cases and introduced me to the world of acupuncture and traditional Chinese medicine (TCM). I was immediately attracted by its analog, right-brained approach and decided to receive formal acupuncture training. When searching for a program, I was fortunate enough to find a very talented instructor in **Dr. med. Michael Fliedner**. Acupuncture has since become an integral – and indispensable – part of my everyday practice. As a **traditional parasympathetic therapy**, it supports and stabilizes the regenerative capacity of the body and lays the foundation for healing. Within the toolkit of complementary therapies, acupuncture is an absolute treasure for the medical profession that can be used to treat nearly all regulatory disorders and sensitivities with outstanding results. But this success also results

in fewer drug prescriptions and associated side effects – a situation that runs counter to the current system of finance feudalism in health care. That is why the statutory health insurers in Germany only refund costs for the treatment of chronic back and knee pain in osteoarthritis cases. **A well-functioning, millennia-old system is thus degraded to a simple pain relief therapy.** And instead of personalized, high-quality treatment from practitioner to patient, health insurers allocate their budget for expensive medications with a variety of adverse effects.

For those not familiar with acupuncture, I would like to illustrate the effects of the meridian system and acupuncture in a brief exemplary summary: situated above the ANS is an additional regulatory mechanism that functions based on energy and information. Our body contains a series of **light conductors** which convey and distribute information through pulsed biophotons over entire body sections at ultra-fast speeds – even faster than the ANS. Chinese medicine characterizes these biophoton conductors as **meridians** and the energy they convey as the **vital energy chi**. Meridians are classified in pairs, the so-called functional circuits, which are associated with specific organs, senses, emotions, and further attributes. I will illustrate these concepts using the example of the **kidney-bladder functional circuit** (▶ **Fig. 31 and 32**): The area covered by these meridians supplying **energy and information** is also known as a topographic location. For the bladder meridian, this **topographic location** comprises the back, the spine, and the bladder. These are also the sites of meridian-specific diseases.

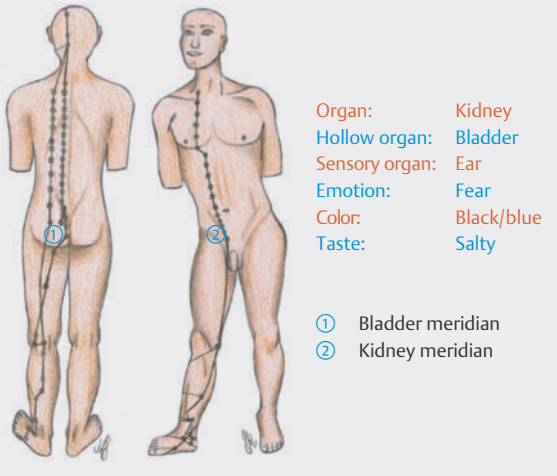

▶ **Fig. 31** Kidney-bladder functional circuit (meridian pair).

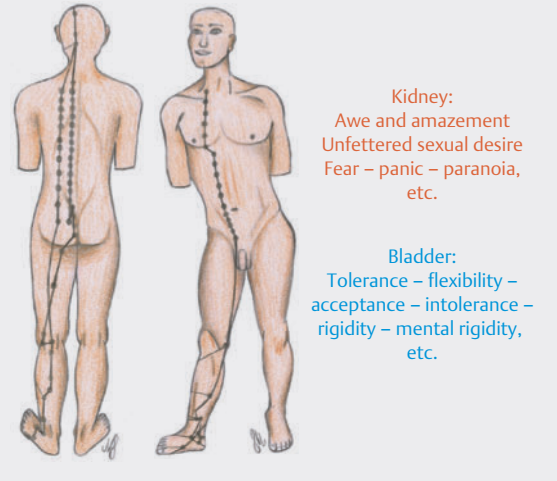

▶ **Fig. 32** Kidney-bladder functional circuit (biographical themes).

In acupuncture, it is common to speak of an energetic abundance or deficiency along the meridians, with the result being that the regulatory function at these sites is often impaired. The underlying causes can be highly diverse. Problems can exist at a purely physical level, such as improper nutrition or insufficient physical activity, triggering changes in the body's essential software that ultimately end in disease. Bio-climatic factors such as heat or cold can have an impact on meridians as well. However, in my experience, the most important causes are the **direct links between meridian function and our emotional and mental well-being**. Our emotions and essential attributes, such as the human will and above all the dominant themes of our biographies, are all reflected by these energetic pathways. **Achim Eckart** beautifully illustrates this interplay in his work on the psychosomatic effects of acupuncture points.

As therapists and practitioners, we are already familiar with the connection between mental and emotional health and disease. Quick-tempered, choleric individuals (overactive liver-gallbladder functional circuit) tend to have liver and gall problems and even gallstones or infections of the gallbladder. More anxious patients (weak kidney-bladder circuit) frequently suffer from bladder infections, back pain, or problems affecting the reproductive organs. Interestingly, through acupuncture and other meridian-based therapies, a single practitioner may be able to cure or improve a variety of disorders in different organ systems. Both during and after acupuncture treatment for back pain, patients will frequently mention that co-occurrent bladder problems or even sleep disorders have either improved significantly or disappeared altogether. This in turn brings relief to the psyche and a noticeable improvement in the body's regenerative capacity.

SOME BASIC PRINCIPLES OF ACUPUNCTURE

- Knowledge of the meridian system fosters a holistic view of human beings and their connection with nature.
- Acupuncture can be used as a holistic method to treat sensitivities as well as disorders at different locations in the body with different symptoms, without the need for costly diagnostic equipment or drugs.
- As a form of therapy that targets the parasympathetic system, acupuncture helps restore healthy rhythms.
- Because of its effectiveness in treating pain stemming from various origins, acupuncture represents a highly promising solution for pain therapy or pain management.
- Through acupuncture, an understanding of the biographical themes associated with the meridians can help patients regain access to their inner selves and enable emotional and mental healing.
- Acupuncture can be successfully combined with other holistic therapies.

Through the lens of meridians, it is immediately apparent that conventional scientific medicine demands a highly cost-intensive approach. It fails to recognize relationships between diseases, which, at first glance, might seem to have zero commonalities in terms of physiological or biochemical factors but which are linked by meridian pathways. For the patient, then, in addition to their general practitioner, this frequently results in visits to numerous specialists for an (often expensive) course of diagnosis and treatment. Another typical example that illustrates how the human spirit (or *chi*) is missing in modern medicine. At this juncture, I want to reiterate that I have only provided a brief overview of acupuncture on these pages. In its entirety, **TCM** represents a complex and effective holistic system that has stood the test of time in Asian culture. In Western culture, we also have well-founded knowledge in **traditional Western medicine (TWM)**, which is in no way inferior to TCM. Both perspectives can stand to benefit a great deal from each other. Based on my 39 years of experience, I feel confident in saying that every physician should be acquainted with alternative techniques, including at least naturopathy as well as anthroposophy and acupuncture. General knowledge of these techniques should be a mandatory component of medical training.

As regulatory therapies, acupuncture and mistletoe injection therapy can be successfully combined (first acupuncture, then mistletoe injections). Both forms of therapy have synergistic effects and even heighten positive outcomes.

Osteoarthritis and spinal degeneration from a constitutional and temperamental perspective

Even though it can only be touched upon briefly, I would like to say a few words here about the topic. Only by perceiving the temperament of our patients can we become real therapists and avoid nocebo medicine.

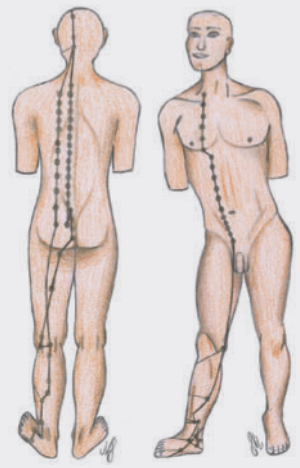

Nephritis/ cystitis:	Urologist
Adnexitis:	Gynecologist
Otitis:	ENT specialist
Anxiety and panic:	Psychiatrist
Migraine:	Neurologist
Sciatica:	Orthopedist
etc.	etc.

▶ **Fig. 33** The kidney-bladder functional circuit: disorders and conventional solutions.

One of the most significant deficits in modern medical science is our failure to consider the individual constitutions of our patients. These characteristics are often passed down from generation to generation, and it is essential to include them in our diagnoses and treatments. Those hallmarks of older (great) physicians have increasingly lost their place in modern medicine. The unsustainable, profit-driven, unidimensional character of conventional medicine ratchets individuality down to a bare minimum, and with it, the possibility of a healing approach that would be less costly in the long term. All complementary therapies endeavor to treat patients as unique human beings and therefore assign a constitution to every individual.

In the **Indian art of healing** or **Ayurveda**, there are three primary constitutions known as the Pitta, Vata, and Kapha types. In **TCM** the guiding forces are organs like the kidney, liver, and spleen. **Western homeopathy** focuses on the individual constitution as the foundation for treatment. Sanum therapy, based on the work of **Prof. Dr. Phil. Günther Enderlein**, distinguish-

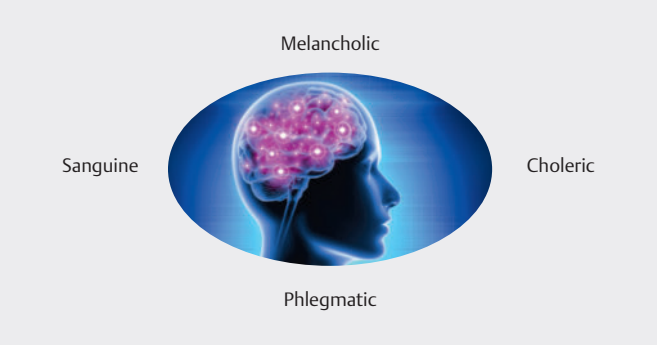

▶ **Fig. 34** Mind and the temperaments.

es between three constitutions or types, a perspective that has been immensely helpful in my practice. The three types often occur in hybrid forms:

The **Mucor type** (congestion and blockage): Mucor types are frequently overweight with a tendency toward hyperacidity of the connective tissues. They often face acute issues with the locomotor system, such as attacks of gout or inflammation of the joints. Above all, they are prone to vascular disorders with consequences such as arteriosclerosis, hypertension, heart disease, or stroke, as well as anabolic imbalances.

The **Penicillium type** (acute inflammation): Those with this constitution tend to develop various forms of ulceration and inflammation, angina, rheumatic disorders, gout, neurodermatitis, and allergies. During childhood, they are frequently afflicted by recurring colds and other ENT disorders.

The **Aspergillus type** (degenerative): This constitution is characterized by an inherent aging tendency (degeneration) in the locomotor system, with sequelae that include osteoarthritis, osteochondrosis, and osteoporosis (all common mistletoe indications). Moreover, soft tissue can also be affected, e. g., lung tissue may respond with fibrosis (or hardening), asthma, and bronchitis. Prostate disease and cysts may also develop in this constitution, which frequently exhibits catabolic imbalances.

How these different constitutions factor into treatment can be illustrated by a few simple response patterns: For congestive Mucor types, anti-inflammatory medications such as diclofenac or aspirin can elicit a positive response. These drugs are also well-tolerated in the long term. The degenerative Aspergillus type usually responds less or not at all to these standard anti-inflammatories. And, finally, the inflammatory Penicillium type tends to react with adverse effects. For patients with active osteoarthritis, treatment with cold packs will often bring good results for the Mucor type, while for the Aspergillus type, symptoms will frequently worsen with this course of therapy.

Based on these descriptions, it is clear that the individual treatment of patients is only possible with the classification into different constitutional categories. Ultimately, it does not matter which constitutional perspective is applied. It should just be a good fit for the individual therapist. In the end, many paths lead to Rome.

As individuals, one of our main tasks in life is to understand and accept our personal constitution, with all of the strengths and weaknesses it brings. Above all, we should take care that our actions are not detrimental to our constitution, causing more harm than good and opening the door for illness and disease. The Mucor type, for example, should adopt an alkaline diet and learn to enjoy sources of energy such as fat, carbohydrates, and protein, and most of all, alcohol, in moderation.

A unique perspective can be found in the **temperament theory** first described by **Hippocrates** (c. 460 BC). Four different temperaments exist in a more or less pronounced state in every individual (▶ **Fig. 34**). Usually, two temperaments are dominant, which can result in highly individual character traits. In the following, I will

SOME BASIC PRINCIPLES OF CONSTITUTIONS AND TEMPERAMENT TYPES

- By considering the individual constitutions of our patients, we have the potential to create genuinely personalized medicine.This goal will not be achieved through increasingly expensive genetic analyses.
- In principle, it makes no difference which system is chosen; the therapist should simply ensure that it is a good fit for his or her personality.
- A truly empathetic understanding of an individual patient not only provides the ideal conditions for healing, but also catalyzes it.
- Standard, cost-intensive, and often ineffective procedures adopted by evidence-based conventional medicine often bring the opposite of the desired results but are justified as scientifically irrefutable.

describe the main attributes of the four temperaments, which have some parallels with the signs of the zodiac. The **Sanguine** ("live and let live") personality type is intelligent, mentally agile, light-hearted, outgoing, enthusiastic, open to new things, highly social and not a fan of boredom, not willing to pursue goals at any cost.

Melancholic ("glass-half-empty") individuals tend to dwell and over-reflect. Even the smallest comments can throw them for a loop. They have a great deal of stamina at work, deep-seated melancholy, and negative expectations.

Choleric ("full speed ahead, no matter what") individuals tend to act out of affect. They can show great enthusiasm but often little patience. They are calm, persistent workers, zealous in the pursuit of their goals, and tend to get into fights.

Phlegmatic ("stoic calm") individuals are emotionally distant, difficult to motivate, relatively stable, not prone to emotional outbreaks. Flexibility or fast reactions are not among their strengths.

As regards these temperaments, I will also provide an example of how they can interact with medicine. Back as a young physician, while ordering a CT scan of the pelvic region of a 50-year-old female patient, I casually remarked that "it could also be a tumor." Two weeks later, I sat with the patient to discuss the results, which luckily came back negative. She confessed that she had spent many sleepless nights worrying about the diagnosis. The patient was a melancholic individual, and my remark had triggered an immense nocebo effect. Since this experience, I have never again used the words tumor or cancer in such situations.

Mistletoe injections – basics

The symptom complex of degenerative diseases

Based on the above-described holistic perspective of osteoarthritis and spinal degeneration, the complex background of these diseases should now be clear. ▶ **Fig. 35** illustrates the different layers of diagnostic and therapeutic intervention associated with the **symptom complex of degenerative diseases**.

In everyday practice, it might not be possible to take all these points into account in every case. Thus, I would once again like to state the cardinal precondition for mistletoe injection therapy.

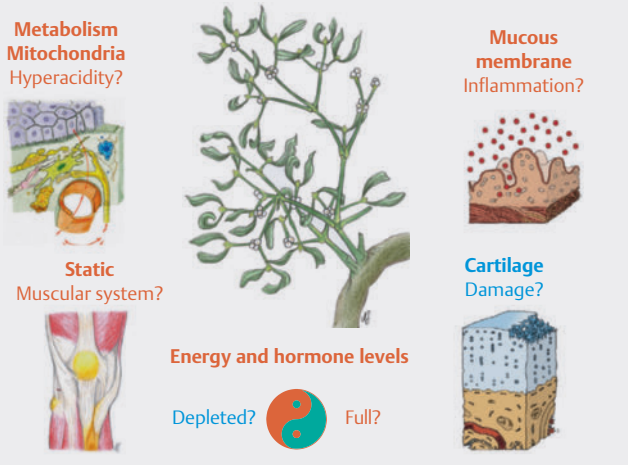

▶ **Fig. 35** Symptom complex of degenerative diseases.

Prof. H. Groh, trial conducted at Hüttenkrankenhaus Burbach, Saarland. Results published in *Münchener Medizinische Wochenschrift* in 1965.

Gonarthrosistrial with 483 patients,
of whom 300 were re-examined
Administration: pure intracutaneous injections

A Physical therapy
B Intracutaneous Plenosol injections
C Cortisone injection
D Cortisone and Plenosol

A 29 % showed long-term improvement.
B 81 % showed long-term improvement.
C 54 % showed long-term improvement.
D 79 % showed long-term improvement.

▶ **Fig. 36** Mistletoe therapy and degenerative disease: Results of an exemplary trial.

Mistletoe therapy and "start-up pain" versus pain from physical stress: If pain increases with movement and stress, the patient most likely has an activated form of osteoarthritis. If pain improves with movement, this points to non-active osteoarthritis

Because mistletoe has a primarily anabolic effect, meaning that it introduces energy into the system, it is not indicated in cases of active osteoarthritis and degenerative disease. **The non-active degenerative symptom complex is the ideal indication for use.**

History of mistletoe therapy

From a medical perspective, the most well-known use of mistletoe is in the field of complementary oncology, where mistletoe is one of the most important and best-researched medicinal plants. It has been used for this indication since 1917, thanks to the groundbreaking findings and methods of **Rudolf Steiner** and **Ita Wegman**. Although it is not as widely known, mistletoe also has a long tradition in the treatment of orthopedic disorders, dating back to the 1930s.

Phytotherapy pioneer **Dr. med. Gerhard Madaus** was the first to study osteoarthritis along with pain-relieving effects and functional improvements that could be achieved using intracutaneous mistletoe injections. The effectiveness of **Plenosol**, an extract he derived from mistletoe that grows on poplar trees, has been documented in a large number of publications. As just one example, I have included the results of a trial by Prof. H. Groh in ▶ **Fig. 36** below.

Since **Plenosol** is no longer available, several anthroposophic mistletoe extracts, primarily derived from **apple tree mistletoe**, have risen in importance. Anthroposophic Medicine has a long-standing tradition of using mistletoe in an orthopedic context. This tradition is evident in the inclusion of chronic joint disease as an indication for mistletoe in the ***Viscum album* Monograph**, published in 1986 by the C Commission (in charge of Anthroposophic Medicine) of the German Federal Public Health Authority.

This indication also appears in a similar monograph published by Commission D, responsible for homeopathy. Both commissions had been tasked with summarizing the then-available body of scientific evidence for individual therapeutic products for revisions to the German Medicines Act. These two medical approaches also offer a wealth of experience and numerous publications on the treatment of orthopedic diseases with mistletoe.

Botany and signatures of mistletoe

The white-berry European mistletoe ***Viscum album* L**. represents a large family of botanicals primarily occurring in the subtropics and tropics. In numerous regions of central Europe, the distinctive spherical bushes are visible in the crowns of coniferous and deciduous trees. Because it does not grow in the soil but on other plants, albeit without significant damage to its host, mistletoe qualifies as a **hemiparasite**. Mistletoe plants can reach an advanced age of 50 years or more. *Viscum album* L. can be further subdivided into three distinct subspecies. Two of its subspecies grow on **fir trees (*Viscum album* ssp. abietis)** or **pines (*Viscum album* ssp. austriacum)**. All mistletoe plants growing on **deciduous trees**, on the other hand, belong to the subspecies ***Viscum album* ssp. album**. Despite significant differences, for example in form, they are genetically identical. Mistletoe lives on nearly all deciduous trees except for beech.

Besides its native habitat, mistletoe exhibits several other peculiarities, a fact that moved the famous botanist **Karl von Tubeuf** to proclaim, "nothing about this plant is normal." Mistletoe is a winter-blooming plant whose growth reveals its distinctly autonomous nature, both temporally and spatially. This exact property prompted **Rudolf Steiner** to apply mistletoe as a medicinal plant in a field of medicine that also deals with diseases characterized by autonomous growth – namely, oncology.

In the following, I will elaborate on similar perspectives that allow us to understand why mistletoe supports the treatment of osteoarthritis and other orthopedic ailments.

Every plant is a visual expression of the **form-building forces** that are active within. One basic tenet of Anthroposophic Medicine, like homeopathy, is that suitable pharmaceutic techniques permit us to transfer a part of these forces into a medicinal remedy. To begin to understand these forces, we start by determining the unique aspects of an individual plant. For that process, we rely on the concept of **signatures**.

The simplest, most easily accessible signature level is the outwardly visible form. One example here is the walnut. Based on its shape, it is assumed to have a positive effect on brain function. Other, higher-level signatures only reveal themselves through a detailed study of a plant. The Goethean method, first practiced by Johann Wolfgang von Goethe and further developed by **Rudolf Steiner** is especially helpful in this regard: careful observations or detailed comparisons with other botanicals lead us to a more complex comprehensive understanding of plants.

In terms of its outward form, mistletoe exhibits similarities with round joints, most prominently ball and socket joints like the shoulder and hip. In particular, it is closely linked to **youth and elasticity – a stark contrast to degenerative aging processes**. Even in older plants, the branches and stems remain green and flexible. They do not lignify (or grow woody) with time. Mistletoe leaves are cotyledon-like (similar to a primary leaf or seed-leaf), giving them an embryonal character. What is more, they are highly **aqueous**. To achieve such a high water content, they actively borrow from the water household of the host tree. In humans, it is a fact that in embryos and babies the water content in the organism is at its highest, and with age, the natural water household slowly decreases. Similar to a young person, mistletoe exhibits a **unique ability to absorb and retain water** in its structures. At points where the first signs of aging occur, like the formation of calcium oxalate deposits in older stems, clusters of berries tend to develop toward the center of the plant as the first sprouts of new life. This ability represents a built-in healing process.

As harbingers of new life, the white berries of *Viscum album* contain various substances, which include **mucous with mucopolysaccharides**. Birds deposit these substances onto the twigs, branches, and trunk of a tree where enzymes, together with the young seedling, dissolve the tree's outer layer. The shoot then penetrates the bark and gains access to the xylem or sapwood, the water transport system of the tree.

Given this behavior, the **dissolving of hardenings or knots** is another prominent signature that describes the healing effects of mistletoe. It is thus the **antithesis of degenerative disorders**, which go hand in hand with a reduced water content in the joints, especially in cartilage, as well as depleted mucopolysaccharide levels. Both of these factors are essential to joint mobility and elasticity.

Another signature of mistletoe manifests itself in the distinct reaction of the winter-active evergreen to

temperature: Delicate mistletoe tissues are largely insensitive to cold and even capable of resisting strong frost. To preserve its water supply through the host in winter, **mistletoe releases its own "anti-freeze" into the transport tissues of the tree**. The consistency of this signature when transported into a therapeutic context is immediately clear: In response to mistletoe injections, the human body often responds by generating warmth. Depending on the dose, mistletoe extract triggers local hyperthermia, especially with intracutaneous injections, and fever with high-dose subcutaneous or intravenous injections.

Considering the wisdom of ancient healers, it is hardly astonishing that in traditional Western medicine, white-berry mistletoe is a medicinal plant with a broad spectrum of indications. These include nearly all diseases accompanied by hardening processes, whether morphological, such as cancer or arteriosclerosis, or functional, such as spasms, or emotional, such as chronic pain or depression.

Effects of mistletoe therapy on degenerative joint diseases

It is remarkable how many scientific findings ultimately confirm the age-old knowledge we have gained through intuition, experience, or concepts such as signature theory.

Research has yielded clear, rational indications for the use of mistletoe in treating degenerative joint diseases, whereby the current findings regarding the pathogenesis of these disorders are congruent with the illustrated effects of mistletoe (▶ **Fig. 37**).

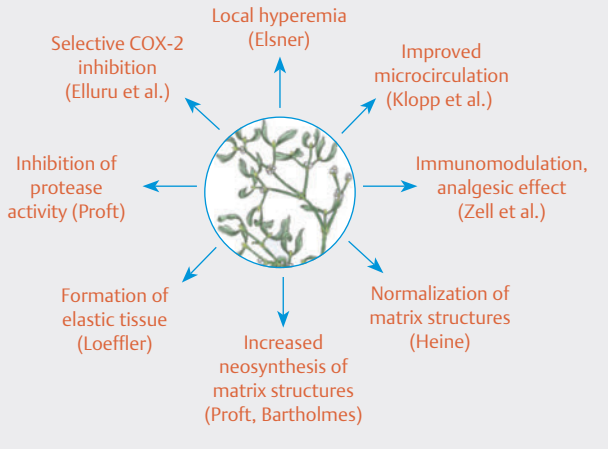

▶ **Fig. 37** Scientifically proven effects of mistletoe therapy relevant to the locomotor system.

Degenerative joint diseases are an expression of a metabolic imbalance between anabolic and catabolic processes (or synthesis and decomposition reactions). This imbalance is especially apparent in bradytrophic (marked by an inadequate blood supply) cartilage tissue, which, especially in overweight patients, is subject to further damage in the presence of overactive catalytic enzymes, for example, high metalloprotease activity. Apple tree mistletoe assumes a special status here due to its ability to stimulate metabolism, an effect that is well-known in Anthroposophic Medicine.

Moreover, and profoundly relevant in this context, a 1980 publication by Loeffler was able to demonstrate that among other effects, mistletoe injections were able to stimulate the formation of new capillaries as well as elastic tissue fibers.

On the other hand, we are also moving away from previous conceptions of "degenerative" disease as a consequence of natural deterioration and starting to understand the importance of **chronic (silent) inflammation processes** in the pathogenesis of osteoarthritis, particularly in the form of chronic synovitis.

The positive effects of mistletoe therapy, which will be familiar to the experienced practitioner, are confirmed by clinical research, although trials in this area remain sporadic. The first randomized study conducted with an anthroposophic extract derived from mistletoe growing on the branches of willow revealed a significant improvement in gonarthrosis symptoms comparable to the effects of the COX-2 inhibitor diclofenac (Stange et al.). This effect persisted for three months after the end of treatment. The latest research reinforces these findings (Elluru et al.).

However, diclofenac comes with significant risks and has long been associated with the development of cardiovascular disorders (in addition to gastrointestinal bleeding). This leads to the reasonable conclusion that **well-tolerated mistletoe extracts have a far more positive benefit-to-risk profile than this standard conventional treatment**. On the whole, mistletoe has proven effective whenever the body's natural water-absorbing capacity, elasticity, and warming/thermoregulatory capacities are either weak or compromised. This compromised state will manifest in a dry, dense, and cool constitution. Locally, the practitioner will be able to confirm stiffness and degenerative processes in the joints which will be cooler to the touch in the afflicted areas. Treatment will reduce swelling in connective tissues and synovia (i. e., joint fluid) production will increase. In addition, the water-binding capacity of the cartilage will improve, leading to firm-

er cartilage structures. Most of all, however, regenerative processes will begin to occur across the structures surrounding the joint, an effect that can be seen quite well in trials. The swelling starts to leave the joints, movement is easier, and pain symptoms usually subside (Bäumler). Patients are generally able to walk for longer distances (with osteoarthritis of the knee and hip) and experience safer, more stable movement.

(For this chapter, I would like to thank Dr. med. Christfried Preußler for supporting me with his extensive expertise on this topic).

Mistletoe indications and stages of osteoarthritis

Degeneration occurs in stages. With the joints of the extremities, the effects of mistletoe will vary depending on the stage of osteoarthritis. In terms of cartilage loss, regardless of whether deterioration is mild or advanced, the results of mistletoe therapy will most likely be positive. Only in cases of full articular cartilage loss will it probably fail to evoke a response.

While an X-ray is not always necessary (based on therapeutic experience), it can be advantageous. Compared to an MRI or a CT scan, X-rays provide a cost-effective and straightforward means of diagnosis, especially for **joint deformations (dysplasias)**. They also permit the practitioner to obtain therapeutically relevant information. ▶ **Fig. 39** provides an overview of the stages at which a mistletoe therapy is likely to be successful. Please note that this overview is merely a global classification and should always be related to the full symptom complex of degeneration.

As a rule of thumb: the more experienced the practitioner, the better his or her intuition in choosing the right treatment. And the older the patient, the higher the likelihood of a positive response to mistletoe.

Because of its anabolic effect, mistletoe therapy often leads to an improvement in general symptoms.

Case example:

An eighty-year-old female patient receives a refresher injection every four weeks to treat her degenerative spinal disease. In the second week after the injection, she regularly and happily reports that her state has improved. She is less melancholic and experiences more vitality. The patient looks forward to her injections. During the winter months, additional therapy with a St. John's wort extract helps to improve her overall well-being.

Progressive deterioration of cartilage

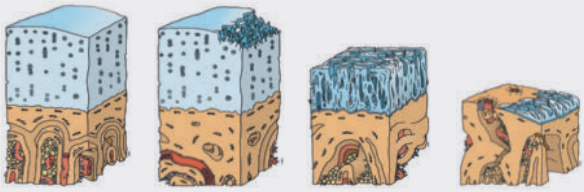

▶ **Fig. 38** Degenerative disease and the progressive deterioration of cartilage.

Osteoarthritis (stages I–III) of the peripheral joints
very good to satisfactory

Degenerative spinal diseases
very good to good

Effect of mistletoe therapy at the target site

Knee joint:	good to very good
Hip joint:	good to satisfactory
Shoulder joint:	good to satisfactory
Thumb saddle joint:	good
Spinal degeneration:	good to very good

▶ **Fig. 39** Effect of mistletoe therapy at the target site.

Mistletoe indications and probability of success for different joints

Experience has shown that with regards to the extremities, mistletoe works best on the knee joint. However, degenerative changes in the shoulder and hip joints, as well as osteoarthritis of the thumb saddle joint, respond well to mistletoe therapy, too.

For degenerative spinal diseases, even cases of severe vertebral joint deterioration and enthesitis, mistletoe therapy has a high success rate and should be attempted. In these cases, too, it is vital to consider the entire **symptom complex of degenerative diseases**.

Mistletoe injection therapy and typical reactions at the target site

One of the main effects of mistletoe injections is the intracellular matrix response, which is also visible on the skin. For this reason, **intracutaneous stimulation therapy** is the preferred method for administering mistletoe extracts in cases of degenerative diseases. In the best-case scenario, redness and swelling will develop around the welt or wheal created by the injection. If an injection is delivered along an acupuncture meridian, it will result in the sustained stimulation of

the meridian pathway for an even greater efficacy spectrum.

The skin reaction at the injection site provides useful feedback for the practitioner and a crucial means of control that should not be underestimated. The local response to mistletoe is always visible and not to be mistaken for an adverse reaction. Instead, it is an **intentional, therapeutically significant healing response**. As a point of comparison, consider for a moment some commonly indicated anti-inflammatories (e. g., NSAIDs), which do their work beneath the skin's surface. Due to their cloaked mode of operation, the effects of NSAIDs can long go unnoticed and, suddenly and without warning, result in gastric ulcers, perforations of the stomach, intestinal bleeding, coagulation disorders, and other serious adverse effects.

▶ **Fig. 40** Injection patterns on the cervical spine.

▶ **Fig. 41** Normal reaction pattern.

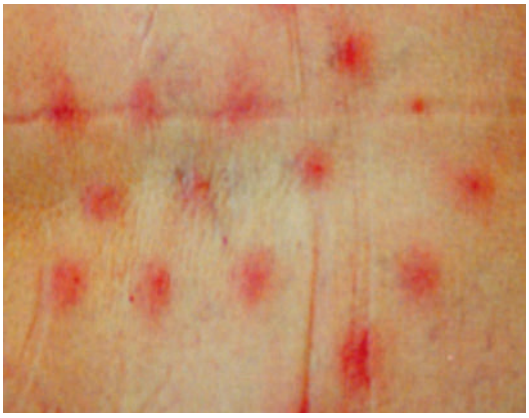

▶ **Fig. 42** Well-defined reaction pattern.

NSAIDs do have their therapeutic value, but they should, in my experience and in the vast majority of cases, only be used for very brief intervals. These products pose substantial risks, since drugs such as ibuprofen or diclofenac are available in small doses without a prescription, a situation that unintentionally fosters widespread misuse and adverse effects. Consequently, it would be wise to ban their use without a prescription. Their low price might seem like a smart budgetary maneuver for health insurance providers, but it is one that will bring high costs down the road.

Mistletoe therapy provides a substantial advantage since its effects are far more sustainable than NSAIDs, and the skin reaction makes its dosage easier to regulate.

In terms of adverse effects, mistletoe injections may prompt an itching sensation in some cases. In very seldom cases, the patient's body temperature may increase by about one degree for 24 hours. Then it can be assumed that the effect of the mistletoe treatment is very positive.

As a general rule: A good reaction to mistletoe usually indicates an improvement in the patient's condition.

Depending on the patient's constitution, the reaction to the mistletoe injection will occur on average after 12–36 hours. Minor swelling and redness will last for about three to five days and in seldom cases, up to ten days. Only after the healing reaction has fully subsided should the next injection be administered. The color of the skin reaction will change as the response fades, going from bright to dark red to reddish-purple and finally brown. During this phase, minor swelling will also diminish. Due to individual differences in skin constitution and type, the responses may vary significantly from patient to patient. **The perceived improvement in symptoms will start to come about during the attenuation phase of the reaction**. An immediate improvement in symptoms is not a trait of mistletoe therapy.

On a biophysical level, it takes time to notice the effects of treatment due to the conversion and regeneration processes happening in the body.

There is a therapeutic trick that can be used to achieve immediate effects.

By diluting mistletoe extract with **procaine** or another **local anesthetic,** a neural therapeutic reflex is activated, which quickly alleviates pain (**immediate reaction**). Even before leaving the clinic, many patients will report that the treated joint already feels lighter and less painful.

▶ **Fig. 40** shows injection patterns on the cervical spine and the patient's response to mistletoe.

The reaction pattern in ▶ **Fig. 41** shows a close-up view of minor redness and swelling.

Skin reactions to mistletoe will naturally vary depending on the patient's skin type. In ▶ **Fig. 42** the response is a normal, well-defined and intense reddening of the skin.

In hyperresponsive patients, very good reactions can be observed as with the knee situation shown below (▶ **Fig. 43**).

As soon as the skin reaction subsides, the red areas will tend to turn reddish-purple (▶ **Fig. 44**). Here, too, significant differences can be observed depending on the individual constitution.

With time, the color of the abated reaction will shift to light or dark brown, and coloring may persist for some time, depending on the skin type (▶ **Fig. 45**). Despite sustained discoloring, it is possible to administer the next injection when necessary.

▶ **Fig. 46** shows a slight overreaction to mistletoe injections on the shoulder. Because of the patient's skin structure and hyperresponsive reaction, the wheals have run into each other.

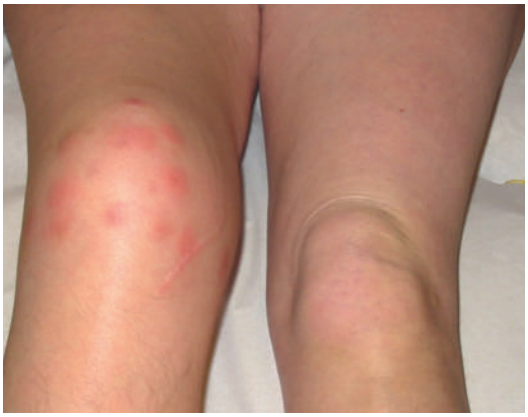

▶ **Fig. 43** Very good reaction pattern.

▶ **Fig. 45** Older reaction pattern.

▶ **Fig. 44** Subsiding reaction pattern.

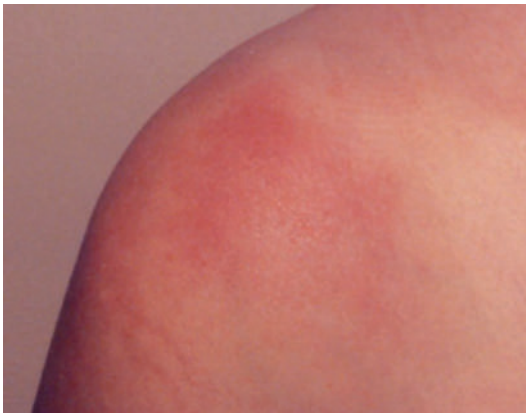

▶ **Fig. 46** Example of a hyperreactive response on the shoulder.

Mistletoe injections – method and procedure

Production of Helixor® M

The white-berry deciduous tree mistletoe *(Viscum album)* used here is found on apple trees. It is used to produce **Helixor® M** (from the Latin *malus* or apple).

Young plants in their entirety, including berries and blossoms, are used in the manufacturing process. Harvest occurs four times a year (in winter, spring, summer, fall), making it possible to capture the different seasonal qualities of mistletoe in one complete extract. All mistletoe plants are sourced from natural environments. Regional plants are collected whenever possible, and the harvest is always done by hand. The summer and fall harvest, as well as the winter and spring harvest, after undergoing maceration, are placed in a five-percent extract. After mixing these extracts, they are filtered, without heat or additives, using a sterile process to ensure a reasonable shelf life. Then, a specific swirling process is applied to create the complete extract. Finally, sodium chloride (NaCl) is added as an isotonizing agent. The result is Helixor® M 50 mg, used as the basis for various dilutions.

▶ **Fig. 47** Botanical components for the mistletoe extract.

▶ **Fig. 48** Required materials. © Erich Jöckel

Required materials

My experience with mistletoe therapy is limited to the poplar and apple tree mistletoe used in an injection solution – at first Plenosol and today **Helixor® M**.

For the injections, we need ampoules with potencies of 10, 20, 30 mg, and, in exceptional cases, 50 mg. Experienced practitioners should be comfortable using just 10 and 30 mg, which I always make sure to have at hand. As a dilution agent and anesthetic, **2 ml ampoules of procaine** can be used in at least a one-percent, and preferably two-percent, solution. Finally, we need 1 ml syringes with ten 0.1 increments (similar to an insulin shot), as well as single-use cannulae or flexible tubes (0.9 × 40 mm) to draw in the extract. Depending on the site and type of application, 0.4 × 19 mm cannulae and 0.5 × 40 mm cannulae can be used for intracutaneous wheals as well as 0.5 × 40 mm cannulae and in rare cases, 0.6 × 60 mm cannulae for deeper injections.

Options for administering mistletoe injections

Single wheal (intracutaneous) injections are a classic method for administering mistletoe. Practitioners administer injections in the patterns detailed later on in this booklet. Initially, mistletoe therapy did not rely on a combined dose of mistletoe extract and a local anesthetic. However, this practice originated during the earliest treatments and is still used today by several practitioners. In my practice, I rely exclusively on dilution series consisting of Helixor® M and procaine or mepivacain.

Intracutaneous wheals and homeosiniatry. In this method, an intracutaneous wheal is centered precisely above an acupuncture point and a small quantity of the solution is injected directly into an acupuncture channel. As previously described, this method delivers

enhanced results. It is also the standard method that I follow.

Intracutaneous wheals plus the infiltration of tendon and ligament insertions
This is the best method of administration for cases of persistent degenerative tendon and ligament problems in the hip and shoulder joints, and especially in the vertebral joints and pelvis. A precise injection into the exact point of pain in the tendon or ligament insertion is crucial here. The same applies for courses of treatment that rely solely on infiltrating the tendon and ligament insertions.

Cortisone infiltration followed by mistletoe injection
In very rare cases, it may be necessary to inject cortisone into a tendon or ligament in the hip or spinal region to gain control over more severe (anabolic) inflammation. Only after such often excruciating symptoms have subsided is it possible to decide on a course of mistletoe therapy.

Dosage guidelines for Helixor® M

As I will explain in further detail in the following chapters, mistletoe is injected into the target site using a standardized injection pattern. Injections are performed using a dilution series containing increasing doses of mistletoe extract. For example, we start with a dose of 2 mg, followed by 4 mg, followed by 6 mg, and so on. We use this gradual approach to find an effective dose for an individual reaction. Each reaction to mistletoe is usually associated with an improvement in symptoms as the reaction starts to wear off.

As a general rule, weekly appointments are advisable, since, for most patients, the reaction will have subsided within that time. Depending on the rigidity of the immune system, it can take anywhere from one to three weeks for the initial reaction to set in.

To chart results effectively, always use a 1 ml syringe. If this quantity is inadequate, two 1 ml syringes are also possible. However, most cases require only small injection quantities. The ampoules needed for the first injections are 10 mg of Helixor® M and 2 ml of 2 % procaine as a dilution agent and a local anesthetic with a neurotherapeutic effect. One graduation mark or score on the syringe corresponds with 1 mg of Helixor® M; two marks equal 2 mg of Helixor® M, etc.

The following standard approach is recommended:

1. First appointment/injection:
   Draw the required dose into the 1 ml syringe using the 0.9 × 40 mm cannula. 0.2 ml from the 10 mg Helixor® M ampoule are equivalent to a 2 mg dose (two marks) in the syringe. Then fill the remaining portion of the syringe (eight marks) with 0.8 ml of 2 % procaine up to the 1 ml mark on the syringe (all ten graduation marks).
2. Second appointment/injection:
   Increase the dose to 4 mg of Helixor® M (four marks) and fill the remainder of the syringe with 0.6 ml of 2 % procaine.
3. Third appointment/injection:
   If you continue to increase by 2 mg, then the third dose should contain 6 mg of Helixor® M (six marks) and 0.4 ml of procaine (the remaining four marks) (▶ **Fig. 51**).

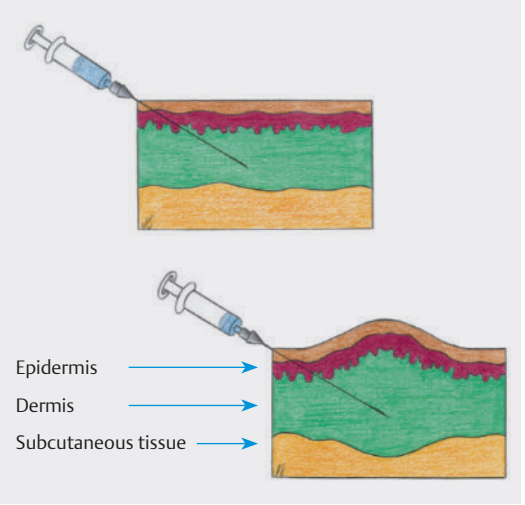

▶ **Fig. 49** Visualization of a wheal.

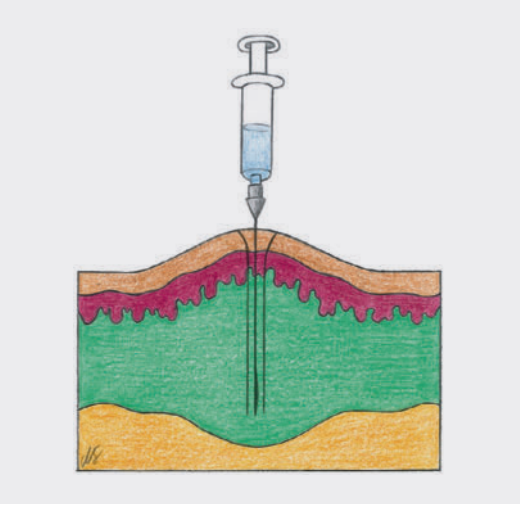

▶ **Fig. 50** Injection in an acupuncture channel.

As a rule of thumb, the older the patient, the higher the initial dose can be.

As previously mentioned, choose the initial dose based on the constitution and probable reaction of the patient. Generally, 2 mg of a 10 mg ampoule Helixor® M has proven to be a sound initial dose, but it is also possible to start with 1 mg for younger or hypersensitive patients or 3 mg for older patients.

For **immediate neurotherapeutic pain relief** using procaine, a further dosage increase is not possible with the 10 mg Helixor® M ampoule, since the accompanying procaine dose would be insufficient. In my experience, it is not advisable to drop below 0.4 ml of 2 % procaine, which makes it necessary to switch to a 20 mg ampoule of Helixor® M.

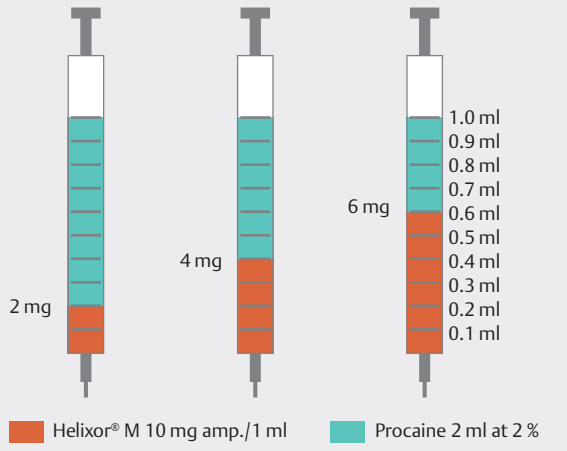

▶ **Fig. 51** Dosage scheme 1 – Helixor® M 10 mg with procaine.

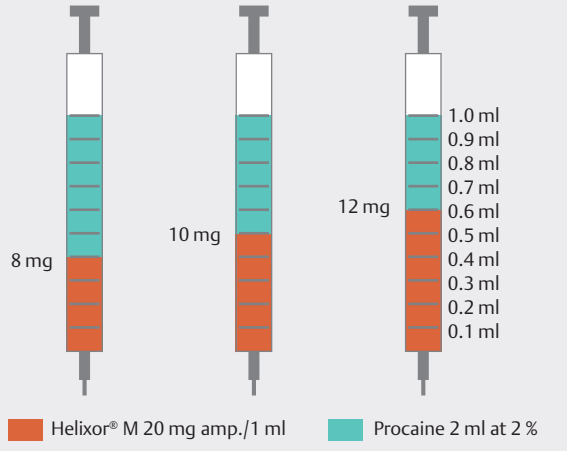

▶ **Fig. 52** Dosage scheme 2 – Helixor® M 20 mg with procaine.

In most cases, four to eight mistletoe injections administered at one-week intervals will suffice. The final dose will then be approximately 12 mg of Helixor® M (accounting for the possibility of unchanged doses after a reaction). If a higher dose is necessary, which is often the case with older patients, Helixor® M 30 mg should be administered. Five marks on the syringe then correspond to 15 mg of Helixor® M, and six marks equal 18 mg.

Because the immune system may become habituated to the effects of the extract, it is possible to increase the last two injections in 3 mg increments.

Progression of a mistletoe injection series

As I have described many times, the patient's reaction to mistletoe and the corresponding improvement in symptoms can vary immensely from individual to individual. Generally, continuous improvement will be observable, as shown in ▶ **Fig. 53**.

Placebo and nocebo effects as basic tools for practitioners

The word **placebo** often has a negative connotation, since the pharmaceutical industry has succeeded in promoting the view that this form of healing is unscientific and worthless. In reality, however, we can also interpret the placebo effect as a positive, stimulating effect on the patient's awareness.

In his book on psychoneuroimmunology and psychotherapy, **Prof. Dr. med. rer. nat. Christian Schubert** summarizes the current state of scientific research on these topics and reveals the enormous potential of this perspective. Every emotional state affects the immune system and therefore the body's natural capacity for healing. Research clearly shows that immune cells are capable of building a variety of substances, including pituitary hormones.

We all know that the doctor-patient relationship is an essential factor in the healing process. A positive outlook, considered action and a calm demeanor are just as important as medical expertise. Unfortunately, we seem to have forgotten a very old trade secret which lays the groundwork for optimum healing: **the art of initiating the healing process through well-chosen words**. From our own medical experience, we also know that the right choice of words can have a positive impact. **But sadly, modern medicine seems to**

have fallen more and more into the nocebo trap. Hectic action, insensitive and overly detailed explanations, as well as expensive and unnecessary diagnostic and therapeutic procedures are the result. Therefore it is an absolute imperative to talk to patients before treatment and explain the expected effects of a **positive reaction to mistletoe**. The skin reactions must be perceived as positive events and not as an allergic reaction. To support patients in understanding mistletoe therapy, I always hand out an information sheet (▶ **p. 55**) that explains the spectrum of reactions to mistletoe.

This handout equips patients with information and gives them a sense of security since various types of irritation therapy no longer fit within the current concepts and methods of modern conventional medicine.

▶ **Fig. 54** illustrates, in my experience, the effects that nocebo and placebo practices can have on the healing process.

Most patients believe that healing occurs continuously from treatment to treatment, although it is widely known that this is not always the case. Patients should therefore always be advised to have patience. With mistletoe therapy, a wide range of reactions can be observed, from immediate effects to a delayed response. The desired curative effects may only be perceived after months of treatment.

Note:
Many patients come in regularly for mistletoe injections once or twice a year. These patients create their own indication and start the healing process on their own initiative.

The intracutaneous administration of Helixor® for orthopedic diseases is not an officially recognized indication or application (off-label use) in Germany. Patients must be informed accordingly and their consent documented. Dedicated forms are available from Helixor for this purpose.

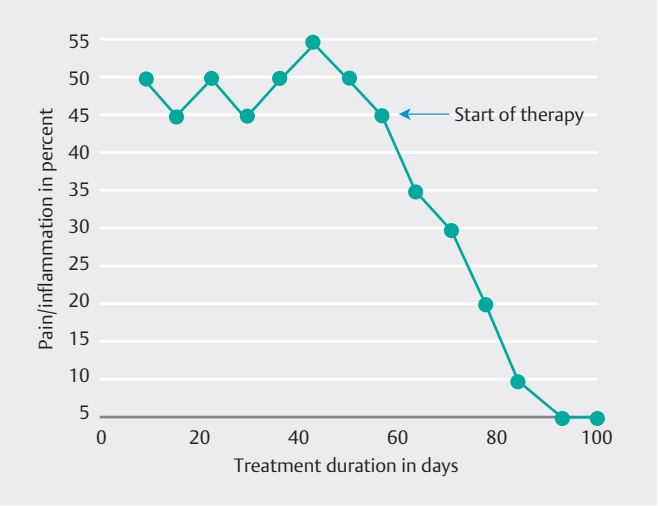

▶ **Fig. 53** Progression of a typical mistletoe treatment.

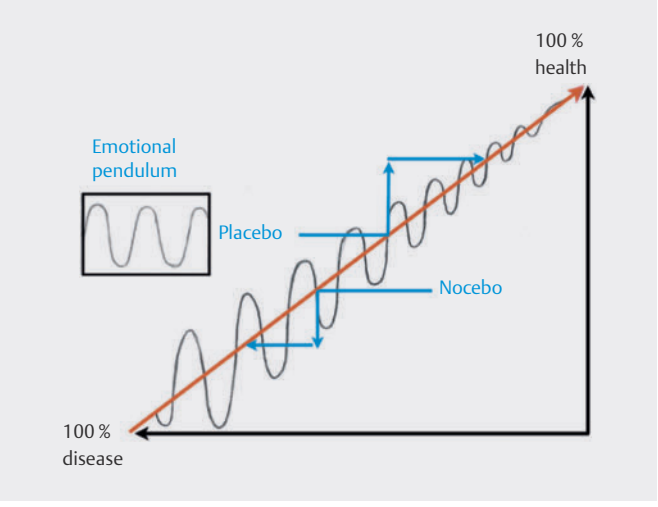

▶ **Fig. 54** Placebo effect/nocebo effect.

Mistletoe injections at the target sites

Injections at the knee joint

The form and size of the knee joint vary depending on the individual. The knee cap (patella) is a helpful guidepost, as it can typically be easily located by touch. The inner and outer joint space can also be used for orientation, though they are sometimes harder to find in the case of a thick tissue mantle.

For the injections in a supine position, it is always advisable to place a cushion or knee roll under the knees to help the patient relax and make it easier to locate the injection points. Injections can also be administered with the patient sitting and the lower leg hanging freely. Make sure to place both wheals slightly above the inner joint space and at the center of the space on either side. The extra injection points are acupuncture points and can be channeled up to two to five millimeters along the meridian, depending on the individual constitution of the patient.

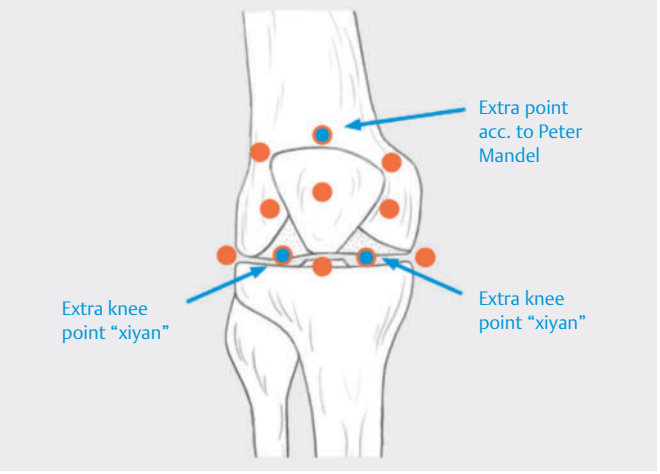

▶ **Fig. 55** Injection pattern on the right knee joint.

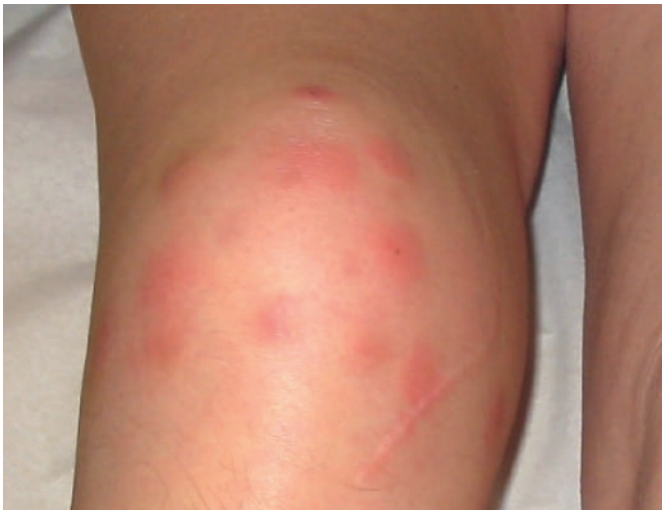

▶ **Fig. 56** Injection pattern on the right knee with a skin reaction.

An infiltration of the tendon insertion may be necessary, but this is seldom the case with increasing age.

▶ **Fig. 55** illustrates the typical injection pattern for the knee joint with acupuncture points shown in blue.

Special care should be taken in this region to avoid infiltrating a vein (especially for varicose veins running across the front of the knee joint). Always perform an aspiration test with the syringe before the injection to prevent excessive irritation. Spider veins do not present a contraindication.

The image below (▶ **Fig. 56**) shows a very good response to mistletoe injections at the knee.

Special considerations for the knee joint

Based on its function, the knee is a synovial joint (condylar joint) in its most stable state when standing (with the leg fully extended). With increasing flexion, and a resulting loss of stability, the knee joint also permits a certain degree of rotation of the lower leg. In addition to the lateral ligaments (e. g., medial collateral and lateral collateral ligaments), two ligaments intersect each other inside the knee (anterior and posterior cruciate ligament) lending additional stability to the joint. When compromised by injury, looseness in these ligaments frequently leads to premature degeneration and severe osteoarthritis in later years caused by poor joint mechanics.

Any successful course of treatment for the knee joint, especially in older patients, should ideally include muscle strengthening exercises. A shortened quadriceps muscle is the cause of most (osteoarthritis-related) complaints of pain behind the knee cap. The state of the quadriceps can be easily diagnosed by having the patient lie on their stomach and asking them to bring

their heel to their bottom. If there is more than a hand's width between heel and buttocks, this is a sign of a shortened quadriceps muscle. Always make sure that the patient's upper legs remain parallel during this test. Stretching is the only way to support healing in this case.

Case example:
A 68-year-old male patient, a former banker, bikes approximately 5000 kilometers each year. In the morning he experiences an increasing level of "start-up pain" in both knees.
With his good muscle condition and an X-ray assessment of osteoarthritis I-II, after receiving five mistletoe injections, he is completely pain-free. This improvement lasts for 18 months, after which a new mistletoe injection series is administered. The patient does regular stretches for his shortened quadriceps muscles (a common condition in cyclists) and takes a regimen of nutritional supplements that includes MSM, glucosamine and chondroitin sulfate to strengthen joint cartilage.

Injections at the hip joint

▶ **Fig. 57** illustrates the injection pattern for the hip joint. Gb-29, located in the lateral hip area, is the only acupuncture point that is sensible to channel (marked in blue). **Injections at the hip joint are always administered with the patient lying on their side.** The top leg should be extended, the bottom leg bent. The patient can place their top hand on the edge of the treatment bed for added stability. ▶ **Fig. 58** shows a very good reaction at the injection site on the left hip.

Special considerations for the hip joint

Anatomically speaking, the hip is a classic ball-and-socket joint that permits a wide range of motion. The taut, tendon-like joint capsule stabilizes the joint most effectively in a standing position. The stability of the hip joint decreases when sitting or in a supine position.

Hip joint arthrosis (coxarthrosis) often presents with pain in the groin region (clearly signaling an irritated joint), as well as pain in the thigh and symptoms of irritation in the peritrochanteric muscles (located around the trochanter), extending in some cases to the back wing of the ilium into the gluteal muscles. In diagnostic terms, it is often difficult to determine whether a single source of pain in this region is responsible for the other symptoms.

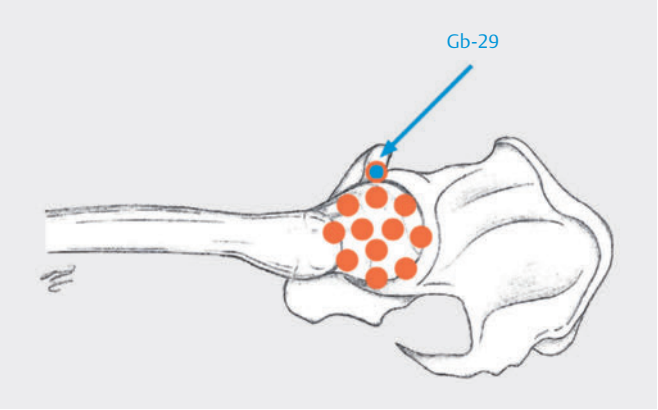

▶ **Fig. 57** Injection pattern on the left hip joint.

▶ **Fig. 58** Injection pattern on the left hip with a skin reaction.

If pain symptoms are more prominent in the groin, intracutaneous wheals are likely to be sufficient. Homeosiniatry may also be considered. If there is pain or irritation where the tendons and muscles connect to the bone, deeper injections into these areas might be required. In all cases, small injection quantities will be sufficient.

Problems with veins are not an issue here, but practitioners must take care not to confuse pain at the muscle insertions with bursitis (inflamed fluid-filled sacs) of the trochanter. Patients with bursitis require an anti-inflammatory course of treatment with NSAIDs, enzymes, Traumeel, etc. or even two or three cortisone injections administered at two-day or three-day intervals. Blockages of the sacroiliac (SI) joint can also mimic hip problems, and sometimes even sustain or result in problems in the hip joint.

For this reason, a thorough clinical exam should always be performed on the patient before initiating therapy.

Injections at the shoulder joint

For the shoulder joint, a variety of different injection patterns is possible. The following scheme has proven beneficial over the years. Three acupuncture points can be channeled. The acromion (or outer end of the spine of the scapula) can be taken as an orientation point. To ensure the correct identification of the injection points, always have the patient sit up straight (i. e., not with a curved back).

▶ **Fig. 59** shows the injection pattern for the shoulder joint with the acupuncture points marked again in blue.

The next image (▶ **Fig. 60**) shows the right shoulder approximately three minutes after a round of injections. Slight redness around the injection points is a typical reaction, as is a small amount of bleeding.

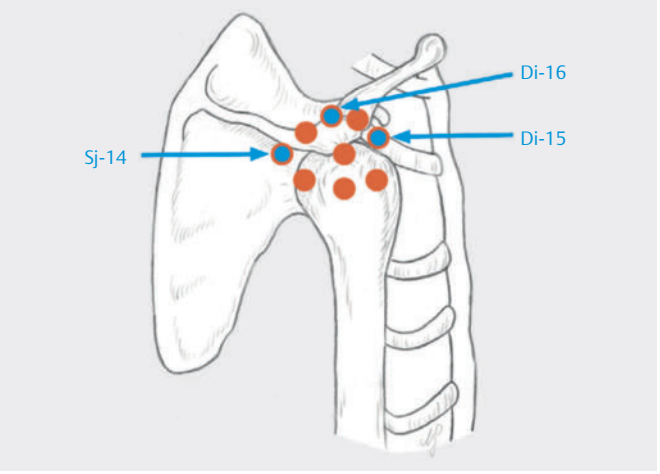

▶ **Fig. 59** Injection pattern on the right shoulder joint.

▶ **Fig. 60** Injection pattern on the right shoulder joint with a skin reaction.

Special considerations for the shoulder joint

Like the hip joint, the shoulder is also a ball-and-socket joint with a broad movement range. The main difference between the shoulder and joints in the lower extremities consists in the lack of stress while standing and walking. Osteoarthritis is less likely to develop in joints not exposed to static stress through everyday activity. True shoulder arthrosis is rare. More common are degenerative disorders of the tendons and ligaments. Given the degenerative symptom complex, these ailments generally respond well to mistletoe therapy.

Because of its distinctive arrangement of muscles and tendons, all meeting in the **rotator cuff**, the shoulder is one of the most elaborate joints in the body. Degeneration is common in this complex system, manifesting as partial ligament tears or rotator cuff tears. Mistletoe can support regeneration in such cases to help regain a tolerable functional level. It is important to note that parallel symptoms in the cervical and thoracic spine may be linked to tension or shortening in the major surface muscles such as the trapezius or deltoids. Such cases almost always require physical therapy as part of an effective treatment.

Great care must be taken during the diagnostic process and in deciding on the next steps for treatment. Extremely painful **inflammation of the bursae (bursitis)** and even acute shoulder inflammation, for example, are not indications for mistletoe therapy but instead require treatment with anti-inflammatories (see hip joint above for details). Due to the acute nature of the symptoms, inflammation of the long biceps tendon connected to the shoulder joint is often not an indication for mistletoe.

Case example:

A 73-year-old female patient with a degenerative constitution suffers from increasing rotator cuff deterioration, resulting in a loss of strength and pain during the use of her arm. A colleague already confirmed the patient's symptoms through an MRI. The patient receives six mistletoe injections, gentle physiotherapy sessions, and ultrasound therapy. Her condition stabilizes; she regains strength in her shoulder joint. Above all, her pain subsides to the point that she can resume everyday tasks. A refresher injection administered at three- to six-week intervals would be advisable in this case as a long-term solution.

Injections at the lumbar vertebrae

Due to the inherent symmetry of the spine and the prominence of the spinous processes beneath the skin and around the posterior superior iliac spine (PSIS), locating the injection points along the lumbar spine usually does not pose a great difficulty. Only with highly obese patients is it sometimes difficult for less experienced practitioners to feel these bony structures. ▶ **Fig. 61** illustrates the injection pattern for the lumbar spine area.

Injections should ideally be administered with the patient in a prone position. For those who cannot tolerate this position, a seated position is a viable alternative.

The photograph below (▶ **Fig. 62**) shows an older injection pattern in the lumbar area with a dark reddish to purplish reaction on the skin.

Special considerations for the lumbar region

While degeneration of the vertebral joints is a classic indication for mistletoe therapy, *Viscum album* has proven very effective in treating a host of degenerative changes to the vertebral discs (not in acute cases), the muscle and tendon insertions as well as degenerative ligament conditions. Similar to the hip joint, it is often difficult to gain reliable access to individual structures through a physical exam. Symptoms in the lumbar spine may also be connected to the hip joint and the sacroiliac (SI) joint. A manual therapy approach to diagnosis will provide significant advantages for the practitioner when it comes to assessing the overall situation.

The lumbar region does not contain any major bursae or ligament structures that due to irritation tend to an acute, hypersensitive reaction and thus are a contraindication to mistletoe therapy. In this case, it is merely important to have a good understanding of the symptom complex of degenerative diseases, since a tendency toward allergic reactions may present a contraindication in some patients. As a general rule, the older the patient, the higher the success rate of mistletoe therapy.

A related case example:
A vigorous 80-year-old male patient and former legal practitioner has suffered for years from chronic back pain. His lower intervertebral disc was already surgically removed. An MRI shows various obstructions along the spinal canal. Despite intensive physical therapy and continued outpatient therapy, there are no signs of improvement. During a visit to a neurosurgical clinic, the patient was told that spinal canal surgery was advisable in his case. After administering acupuncture and eight rounds of mistletoe injections, 80 % of the patient's symptoms improve. The patient switches to an alkaline diet that is low in animal protein, gives up his tennis matches and starts to swim regularly.

Injections at the cervical vertebrae

The injection pattern for the cervical spine is illustrated in ▶ **Fig. 63**. Because of the large number of lymph vessels in this region, only very small intracutaneous wheals should be created and little to no liquid injected into the acupuncture meridian depending on the individual constitution of the patient. The injection can

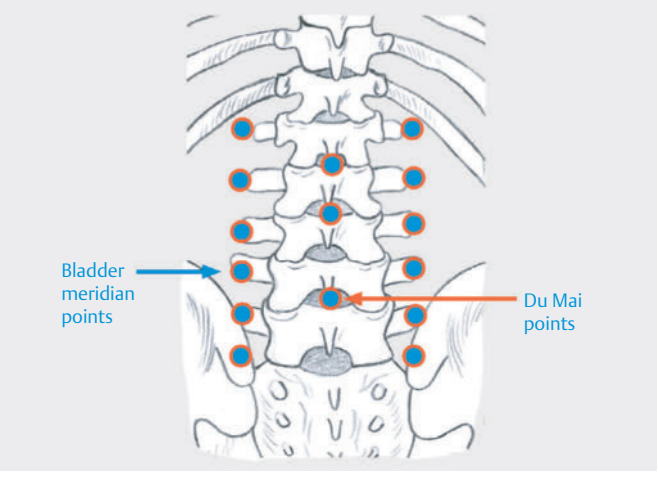

▶ **Fig. 61** Injection pattern for the lumbar region.

▶ **Fig. 62** Injection pattern for the lumbar spine with an older skin reaction.

then be optimized once the practitioner gains experience (▶ **Fig. 64**).

Special considerations for the cervical region

Pain in the cervical area related to degenerative changes such as vertebral arthrosis, degeneration of the intervertebral discs, and irritations of the tendons and ligaments are all common problems we see in everyday practice. Given the close link to the autonomous nervous system with sympathetic ganglia (nerve cell clusters) located below the transverse processes, more or less pronounced neurological symptoms may also develop due to connections with the cerebellum, such as dizziness and vertigo. Similar symptoms can emerge due to connections to the inner ear, including tinnitus.

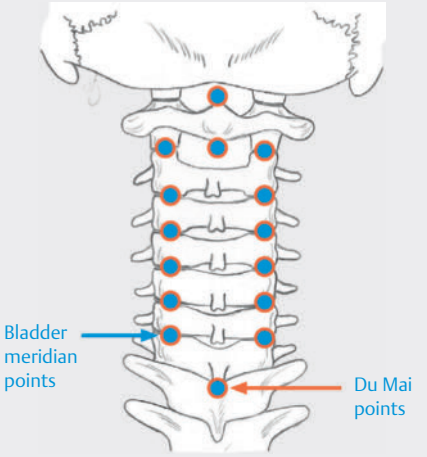

▶ **Fig. 63** Injection pattern along the cervical spine.

▶ **Fig. 64** Fresh injection pattern along the cervical spine.

The two posterior vertebral arteries running through a bony channel on either side of the neck (arteria vertebralis) supply blood to the cerebellum, the brainstem, and parts of the inner ear. Arthroses of the small vertebral joints of this channel can cause obstructions to this pathway, provoking further neurological issues. Symptoms are often the result of numerous triggers and therefore a prime indication for mistletoe therapy.

A related case example:
A 68-year-old female patient has suffered for years from chronic pain in the cervical spine radiating into the head. She also experiences frequent bouts of mild dizziness that force her to seek company whenever she needs to leave her home. An MRI reveals significant degeneration of the cervical spine, narrowing of the spinal canal, and a probable obstruction in the arteria vertebralis. After the second appointment for mistletoe injections, she starts to experience an improvement, and after eight injection series, the patient's health has been restored to a condition appropriate to her age. The patient has regained the ability to perform all everyday tasks and no longer complains of dizziness. Once a week, she attends manual therapy sessions on my advice and does daily mobilization exercises at home.

Injections at the thoracic vertebrae

▶ **Fig. 65** shows an injection pattern identical to those for the other two vertebral segments. If the patient experiences pain radiating along one or more ribs, it is advisable to administer intracutaneous wheals over a larger area, which is why I also refer to this form of injections as **field-type intracutaneous wheals**.

▶ **Fig. 66** gives a glimpse of a typical series of field-type wheals in the thoracic region.

Special considerations for the thoracic region

Compared to the other main segments of the spine, the thoracic spine is unique in that it connects to the ribcage. In addition to paired vertebral joints, there are two joint facings on each side between the individual vertebrae and ribs. These joints enable rib movement at the thoracic vertebrae and they can exhibit degenerative changes. Such changes can also result in pain occurring along the length of a rib and even extending into the anterior thorax. This pain can often mimic cardiac symptoms. Mild to medium thoracic vertebrae pain at rest and in motion, difficulty taking deep

breaths, a sensation of blockage while breathing, and symptoms when changing positions in bed are frequent. Taken together, this entire symptom complex presents an excellent indication for mistletoe therapy.

Case example:
A 64-year-old female patient has several acute episodes of cardiac arrhythmia and pain each year. Although she undergoes an intensive cardiological examination, her doctors cannot locate any cause. Then, a radiological exam shows significant degenerative changes in the thoracic vertebrae. I administer mistletoe injections as field-type intracutaneous wheals, and after gradually increasing to a dose of 18 mg Helixor® M, the patient receives a *refresher injection* every six weeks. The cardiac symptoms disappear, but reemerge whenever the patient fails to receive follow-up injections for several months. She notices that her diet, which is rich in carbohydrates, tends to aggravate her symptoms. So she receives additional therapy in the form of alkaline powder and baths as well as homeopathic supplements to support organ function. Because a full blood count turns up a potassium deficiency, she takes regular potassium supplements before sleeping at night.

Thumb saddle joint

This localization of osteoarthritis (rhizarthrosis) most frequently affects women; occurrences of the disease are very seldom among men. Common symptoms include swelling of the joint together with more or less prominent atrophy of the muscles at the base of the thumb. As the disease progresses, abduction of the thumb becomes increasingly difficult.

From a radiological perspective, this form of osteoarthritis usually corresponds with a limited abduction of the saddle joint. The disorder responds well to mistletoe injections (▶ **Fig. 67**). As a complementary measure, manual therapy or physiotherapy should be prescribed with a clear focus on extension (traction). Creating more space in the capsular area will result in noticeable improvements. With a basic grasp of manual therapy, it often suffices when the patient performs easy traction exercises themselves.

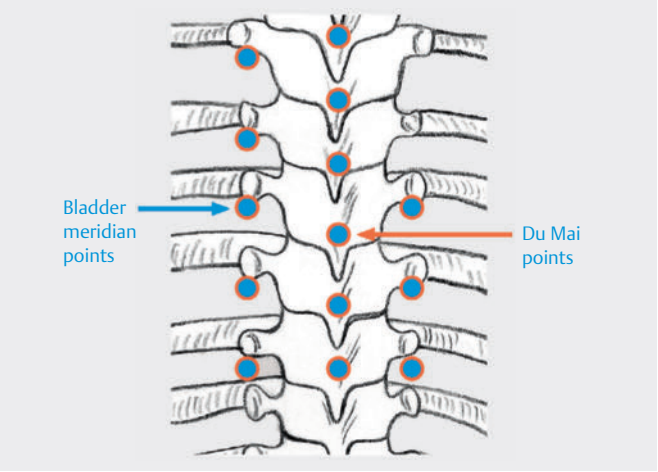

▶ **Fig. 65** Injection pattern along the thoracic spine.

▶ **Fig. 66** Injection pattern in the thoracic region with field-type intracutaneous wheals.

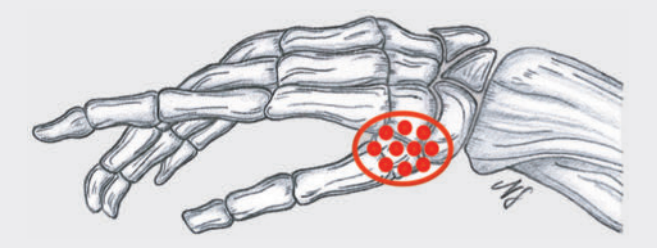

▶ **Fig. 67** Injection pattern at the thumb saddle joint.

Special indications for mistletoe therapy

Persistent heel spurs

Generally, heel spurs or tendonitis of the foot (not the Achilles tendon) pose a difficult therapeutic challenge. This condition affects the plantar fascia and the attachments of the short foot flexors. The medial portion of the soleus muscle also plays a role. Individual stretches may be helpful.

However, this condition usually stems from a major static imbalance. SI irritations are not uncommon. Besides traditional insoles (or sensomotoric insoles when necessary), physiotherapy with stretching of the short foot muscles as well as a gait analysis and subsequent improvements, mistletoe therapy can also be attempted for chronic heel spurs. It should be administered through a few small intracutaneous wheals on the outer side of the heel (▶ **Fig. 68**).

▶ **Fig. 68** Injection pattern on the right heel.

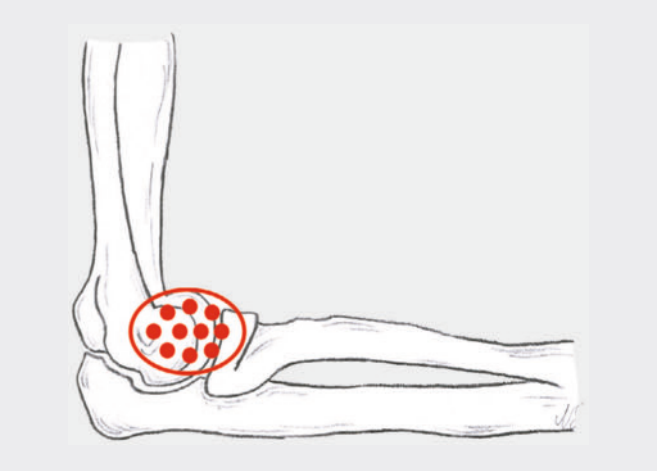

▶ **Fig. 69** Injection pattern on the right elbow.

Chronic epicondylitis (tennis elbow)

Chronic tennis elbow tends to be extremely resistant to therapy; every practitioner has their own experiences with this problem. Possible courses of treatment include electrotherapy, physiotherapy, injection therapy, manual therapy, ointments as well as the application of the Baunscheidt method. Another option is mistletoe injection therapy. Alongside intracutaneous wheals, injections can also be administered into the ligament endings of the extensors at the lateral (outer) epicondylus. ▶ **Fig. 69** illustrates the injection pattern.

Chronic ligamentitis on the dorsal pelvis and the spine

Different forms of ligamentitis affecting the dorsal pelvis can also prove highly resistant to therapy and trigger pain radiating into the legs. The posterior superior iliac spine is often the source of irritation since it is the insertion point for various ligaments. The sacroiliac ligaments, the iliolumbar ligaments running from the PSIS to the fifth lumbar vertebrae and the interspinous ligaments or ligament structures between the dorsal spinous processes are all common indications for mistletoe injection therapy. Here, too, the degenerative symptom complex should be reliably diagnosed as the main cause of pain before commencing therapy.

In practical terms, a small amount of mistletoe extract is injected using a syringe that is long enough to reach the ligament ending. Additional tiny pricks can be introduced over a small surface, like with sclerosing treatments, as needed. *Viscum album* injections, as it is well known, lead to the formation of new elastic fibers in the ligaments.

The extract should never be administered as an intramuscular injection. ▶ **Fig. 70** shows a number of important ligament structures.

Tinnitus and hearing loss

Neither symptom presents a direct indication for mistletoe therapy. Nevertheless, if degenerative changes are present in the cervical spine, it has been my repeated experience that both symptoms can be improved, albeit to varying degrees. Injections containing a minimal quantity of mistletoe extract can be performed at the mastoid process (▶ **Fig. 71**). One to four small intracutaneous wheals can be placed above the clearly palpable process and then at a deeper level – but only in chronic cases. Note: Remember that it is extremely difficult to differentiate between ligament and muscle attachments for diagnostic purposes.

Dizziness

This indication is covered above in the section on mistletoe injections at the cervical spine. Ultimately, good results will always be achieved when the symptoms are tied to a degenerative disorder affecting the cervical vertebrae.

Slipped or herniated disks

An acute slipped disc is not an indication of mistletoe therapy. Immediate action, especially pain management and pain therapy, is required in the form of an anti-inflammatory drug (oral and parenteral). Physiotherapy should be prescribed in nearly all cases. It is often necessary to include the entire range of therapeutic options.

Mistletoe therapy is indicated for older prolapsed discs that repeatedly trigger pain and discomfort, especially in conjunction with degeneration and its symptom complex. Due to the multitude and diversity of degenerative disorders, the cause of the symptoms may not always be identifiable. However, the same basic principles for mistletoe therapy may be followed as described for the different segments of the spinal column above.

Case example:

One of my long-time patients, a 53-year-old woman, complains for weeks about pain in the mid-section of her thoracic spine, which came about after an extended period of resting on a reclining lawn chair. The symptoms occur intermittently and are an increasing source of discomfort. Following a clinical exam, I confirm age-appropriate function and sensitive vertebral joints. After three injection series with *Viscum album*, the patient's pain disappears entirely and does not return. An MRI performed at the patient's request shows an older prolapsed disc in the painful segment.

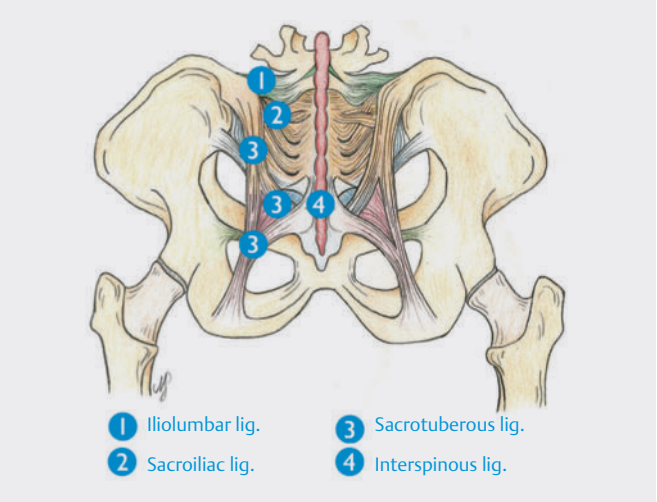

▶ **Fig. 70** Posterior pelvic ligaments.

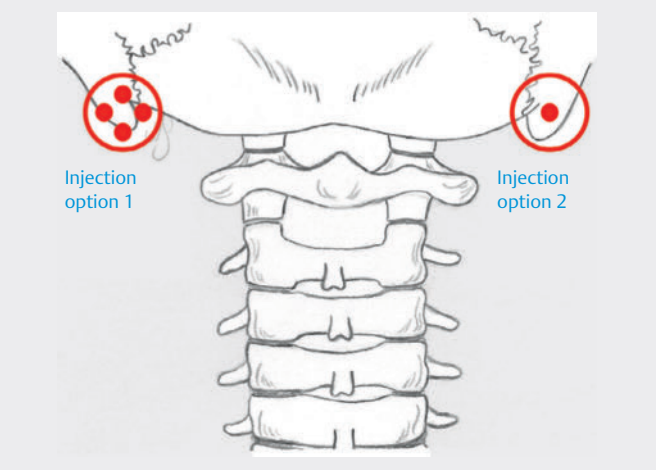

▶ **Fig. 71** Injection pattern at the mastoid process.

Osteoporosis and mistletoe therapy

Conventional scientific medicine has laid out an evidence-based concept for the treatment of osteoporosis. Due to my experience in the field of biological medicine, I only integrate this concept into my practice to a minimal extent. Among other measures, it consists of senseless daily calcium and low-dose vitamin D3 supplements, as well as expensive bone-building drugs with significant side effects.

But to develop an efficient complementary approach, we need to start with a solid understanding of bone function. The bone consists of a network of vital bone cells directly embedded in the extracellular matrix of the bone. These cells fall into three different categories. Depending on their function, we can distinguish between cells that build **(osteoblasts)**, maintain **(os-**

teocytes) or deconstruct **(osteoclasts)** bone substance.

About 25 % of the extracellular matrix, more or less the "primal" matrix, is composed of organic substances such as silicas (silicon), glycoproteins, proteins, and type I collagen. Inorganic materials (95 % calcium occurring as carbonate and phosphate; 5 % magnesium along with fluorine and boron), especially hydroxyapatite, lend the matrix the essential rigidity required for strong, stable bones.

Contrary to popular belief, demineralized bone becomes soft, not brittle. This characteristic is easy to confirm by placing a chicken bone in a hydrochloric acid solution. The resulting bone structure is flexible and rubber-like.

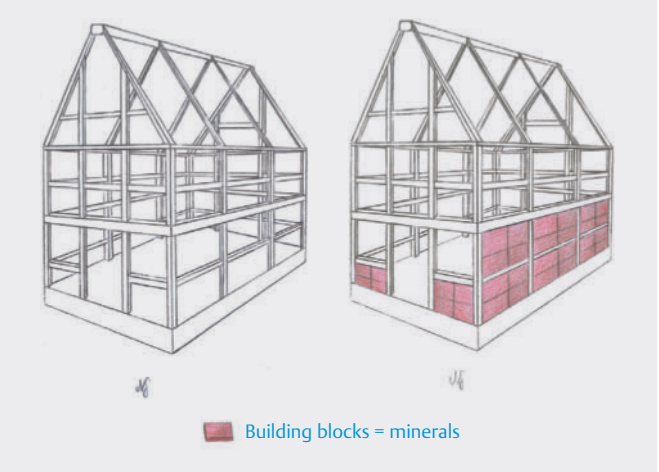

▶ **Fig. 72** Model of the primal matrix of the bone with built-in minerals.

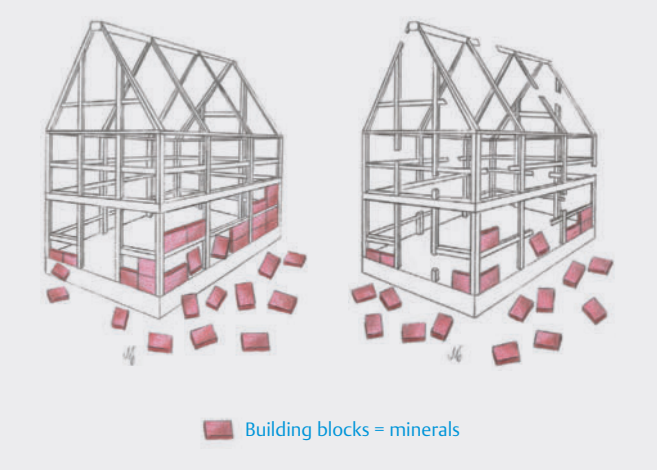

▶ **Fig. 73** Two causes of osteoporosis: immobility vs. degenerative changes.

Insufficient use of the locomotor system (e.g., as experienced by astronauts or as the result of inactivity due to a cast) can result in the demineralization of bone substance. But, and this is key, the primal matrix remains completely intact. Only in such cases would a calcium regimen be advisable in addition to conventional muscle mobilization exercises. Muscle contractions and gravity are ultimately the main incentives for calcium absorption in the bones.

In cases of osteoporosis, however, the organic primal matrix is partially lost, and with it, the essential ability to store calcium for bone strength. The bone structure then becomes brittle. Osteoporosis is a catabolic disorder that falls within the symptom complex of degeneration. ▶ **Fig. 72** shows a normal bone structure (aptly illustrated as a half-timbered construction) and ▶ **Fig. 73** illustrates two different forms of osteoporosis: On the left, prolonged immobility results in a simple loss of bone minerals (red building blocks) while the basic structure remains intact. On the right, degenerative changes cause the breakdown of the actual building framework.

Bone erosion is evident in increasing coarse bone structures and fractures, as shown schematically on a segment of the spinal column in ▶ **Fig. 74**.

In therapeutic terms, treatment can happen on different levels: **acupuncture to recover regenerative capacity** (where kidney *chi* is in a weakened state), anabolic supplements such as (plant-based) **proteins, vitamin D, anabolic minerals** (magnesium, boron, fluorine) and **anabolic hormones** (see the section on the Rimkus method). As a mineral, calcium has a catabolic effect and will never suffice as a sole therapy or preventive measure.

Targeted muscle training is another proven component in a holistic approach, just like magnetic field therapies, which have been shown to improve osteoblast activity.

Alongside minerals, vitamins can also be used as nutritional supplements. Vitamin B promotes bone metabolism. Vitamin C is required for the production of type I collagen. Vitamin K2 regulates the processing of minerals, and vitamin D supports the integration of calcium in bone tissue.

Osteoporosis results in several degenerative changes that cause significant pain. Mistletoe injection therapy is a promising course of treatment. The anabolic effects of mistletoe support an increase in bone density. The stimulation of muscle growth can stabilize

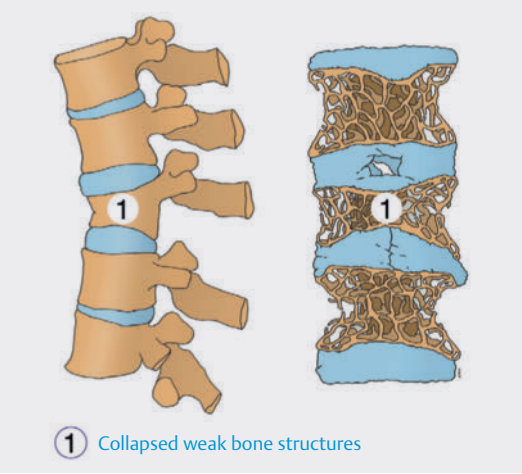

▶ **Fig. 74** Loss of bone substance due to osteoporosis.

▶ **Fig. 75** Spinal injections on a patient with severe osteoporosis.

further degenerative changes to the vertebrae, also helping to reduce pain. Mistletoe therapy has been shown to improve the patient's condition on several levels in cases of osteoporosis.

On the whole, the efficacy spectrum of mistletoe injections for the treatment of osteoporosis is similar to that of degenerative spinal diseases.

However, mistletoe therapy is not indicated in cases where the patient has an acute spinal fracture. In such cases, treatment should only be initiated during the healing phase, after six to eight weeks. On the other hand, osteoporotic sintering in all its forms (or the gradual vertical loss of bone structure) is a promising indication for mistletoe therapy.

▶ **Fig. 75** shows a patient who has received mistletoe injections along the entire length of her thoracic and lumbar spine. This is a typical case of degenerative osteoporosis in a 50-year-old woman with extreme hormone deficiencies triggered by a hysterectomy as well as the removal of both ovaries due to a tumor disease.

Practical information and advice on mistletoe therapy

Positioning

Always make sure that the patient is in a stable and relaxed position when administering injections. For injections at the knee, a knee roll should be used. When the focus of treatment is the lumbar region, the patient should ideally be in a prone position; a pillow in the lower abdominal region can support and relax the surrounding area. If the practitioner's table has a tiltable headrest with a face cradle, the injections in the cervical region can be performed in a prone position. Otherwise, they should be administered, like for the shoulder area, while the patient is seated. For the hip joint, as described above, the treatment should take place with the patient lying on their side.

Control mechanisms

We are all unique individuals with personalities situated somewhere along a spectrum from **the extremely reserved and cautious to the bold, risk-taking types**. So, too, will each practitioner have their unique approach to mistletoe therapy. Generally speaking, it is advisable for the first injections to generate relatively small wheals, at least in sensitive regions like the cervical spine. Depending on the individual patient, it may not be wise to force a noticeable reaction during the first session. Procaine or another anesthetic for diluting the injection will invariably have an immediate effect. For highly sensitive patients, I recommend starting with a 0.1 mg dilution series of Helixor® M and increasing the dose very gradually in 0.1 mg intervals.

If you decide, in addition to the wheals, to inject the solution into acupuncture points (which tends to be the norm), the depth of the injection and the quantity of the injected solution can serve as additional control mechanisms. Please remember that small quantities will suffice to achieve a therapeutically significant and effective reaction. The required quantities can, of course, vary with extremely rigid matrix conditions or advanced age.

Once a reaction has set in, wait to administer the next mistletoe injection until redness is no longer visible and swelling has completely subsided: Remember, it is never wise to pour oil onto a burning fire! Follow-up visits at one-week intervals are therefore recommended since most reactions will have disappeared within this time frame.

Explain to patients that a noticeable reaction to mistletoe is a good sign that positive effects are likely to follow.

Depending on the mistletoe reaction, the next injection should either be administered without an increase, that is, using the previously applied dose, or even reduced by 0.1 or 0.2 mg of Helixor® M. In rare cases, patients will show a consistently desirable reaction to a certain dose (e.g., 3 mg Helixor® M) and an increase will simply not be required.

Refresher injections

Older patients with significant degeneration and poor anabolic activity are usually no longer sufficiently mobile. They require more intensive therapeutic care and are not able to do mobilization exercises. After a round of mistletoe injections, for example with a dose of 15 mg of Helixor® M, that brings about a noticeable improvement, I recommend proceeding with "refresher" injections using the last administered dose (final dose) at four- to six-week intervals. This approach makes it possible to manage the degenerative condition. At the same time, thanks to the positive effects of mistletoe on the system (general stimulation and strengthening), synergetic effects such as a better mood, more energy, drive, zest, and light-heartedness may be noticed in daily life.

Rare and hypersensitive reactions

Depending on the patient's constitution, the desired reaction to mistletoe will vary. As a general rule: **the more intense the reaction to mistletoe, the more positive the results.** Stronger reactions can involve a certain level of discomfort, often manifesting as an intense itching sensation. In most cases, the patients will have no difficulties tolerating the symptoms if they have been informed in advance about the course of the therapy and possible reactions. That is why it is always advisable to share the patient information sheet before the first injections (▶ **p. 55**).

In one in one thousand cases, **mild local swelling of the lymph nodes** can occur without any further complications. Patients who tend to an extreme reaction of the ANS can also experience an increase in body temperature up to 38 °C (100.4 °F). This reaction is sel-

dom, however, and ultimately harmless. Fever intensifies healing, especially when it comes to ANS disorders.

Important: Less experienced practitioners often tend to interpret these strong reactions as an allergic response. However, genuine allergic reactions beyond the desired effects are rare. Patients with allergic reaction patterns (such as neurodermatitis patients) may react to mistletoe with a response in a different skin region.

In the event of hypersensitive reactions, the appropriate response is a local reduction in inflammation. For skin reactions, I recommend Combudoron Gel or Ointment or Calcea Creme. Should swelling occur in the lymph nodes, it is possible to prescribe the short-term use of a non-steroidal anti-inflammatory drug (NSAID) (for one to two days) or an antihistamine. Local cooling may also help to ease the symptoms.

Generally speaking, the mistletoe reactions I have seen in my years as a practitioner have always been manageable and responded well to therapeutic measures. When the guidelines and indications for mistletoe therapy are properly observed, hypersensitive reactions are a very seldom occurrence.

Contraindications to mistletoe therapy

The Summary of Product Characteristics provided by the manufacturer lists the following contraindications:

- Known allergies to mistletoe preparations.
- Acute inflammatory or highly febrile diseases: treatment is to be interrupted until the inflammatory symptoms resolve.
- Chronic granulomatous diseases, and florid autoimmune diseases or those under immunosuppressive therapy.
- Hyperthyroidism with tachycardia.

As a general rule for the off-label uses described here: **acute (anabolic) disorders of the locomotor system (e.g., acute osteoarthritis) are never an indication for mistletoe therapy.**

Particular caution should be taken with cases of tendovaginitis (or inflammation of the tendons in the hands and feet). Mistletoe is explicitly not to be used on the Achilles tendon. Cases of bursitis, especially at the knee and hip, are an additional contraindication.

Always be aware of superficial veins, which can quickly become inflamed if accidentally injected. Especially for injections administered at the knee joint, proceed with care and only place wheals next to clearly visible veins.

Adjuvant treatments and mistletoe therapy

Adjuvant medication

Patients have been known to complain about long lists of drug prescriptions. However, the term *drug* or *medication* includes a wide range of remedies. In fact, there are four basic types of substances, which I will briefly describe here:

Conventional, scientifically derived medications:

These drugs activate a switch in the body that suppresses a specific symptom such as hypertension, an allergy, dizziness, pain, etc. Often, treatment is lifelong. If the patient stops taking the medication, their symptoms will invariably recur because the cause was not treated or eliminated. Moreover, the risk of adverse effects tends to be significant.

Substances from regulatory therapy approaches:

These substances always bring about an improvement in the body's internal regulation and can lead to a permanent improvement. They are administered for a few days and sometimes weeks, but rarely over several months. They include phytotherapeutics, all forms of homeopathy, medicinal teas, etc. Side effects are extremely rare.

Nutritional supplements:

As their name suggests, these products are meant to supplement certain substances that are lacking in the body and whose deficiency results in various symptoms (for example, arrhythmia in the case of potassium deficiency or a compromised immune response with a zinc deficiency). In addition to minerals, supplements can include vitamins, proteins, fats, etc. Nutritional deficiencies can occur as a result of malabsorption syndrome, digestive insufficiency, elevated dietary requirements, or simply poor nutrition. Such deficiencies obviously cannot be restored through simple dietary changes and it often takes three to six months to regain healthy blood and tissue levels. Adverse effects can occur if supplements are taken for a prolonged period.

Hormone supplements:

Meanwhile, hormone supplements are widely accepted for the treatment of thyroid disorders and diabetes mellitus and no longer the subject of debate. Now, we are also making in-roads with bioidentical reproductive hormones such as progesterone and estradiol, and starting to rethink some prior assumptions. Empirical research has shown that both during and after menopause, hormone replacement therapy has resulted in significant improvements to the general health and well-being of patients. This form of treatment is lifelong; adverse effects are seldom with proper use.

Deacidification and mistletoe therapy

Healing processes in the locomotor system can only occur in an alkaline milieu. Therefore, the accompanying use of an alkaline supplement is advisable for a four- to six-week period or at least for the duration of mistletoe therapy. If a full blood count is not available, a low-mineral alkaline powder (or tablets) such as Alkala N can be safely used.

To avoid any interference with digestion in the stomach, the following procedure has proven useful: In the morning, mix one normal or heaped teaspoon of powder into 0.2 to 0.3 liters of lukewarm water. Drink the solution at least 20 minutes before breakfast. The alkaline supplement can then pass immediately through the stomach and into the small intestine where it is absorbed. The body then has an immediate boost in alkaline valency.

If a full blood count is available, specific deficiencies can be targeted and restored using a mineral-rich alkaline powder.

When I first see an osteoarthritis patient, I start by prescribing six weeks of abstinence from animal protein. The patient will experience decreased inflammation, weight loss, and reduced strain on the joints. During the six weeks, the liver, kidneys, lymphatic system, and connective tissue will also contribute to the detoxification process. Alkaline infusions will also produce very rapid effects, and they have proven their worth in my practice. As a rule of thumb, plan one full month of deacidification for every year of exposure to an overly acidic diet.

Over the past two years, several pracitioners have found various approaches to intermittent fasting (e.g., the 16/8 method) to be both practical and effective for

the detoxification of the cells and connective tissue. In this context, **Univ.-Prof. Dr. rer. nat. Frank Madeo** at the University Hospital Graz in Austria demonstrated the specific effects of the substance spermidine. Found not only in human sperm, this substance is formed inside cells after a fasting period of at least 12 hours. Once it is present in sufficient quantities, spermidine initiates a clean-up process in the cell. Any "loose ends" are rounded up, broken down, and recycled, and waste products are excreted. Professor Madeo confirmed the health-enhancing effects of intermittent fasting in a series of trials on animal subjects. The described impact helps explain the success of the 16/8 method, which involves 16 hours of fasting, followed by 8 hours in which two meals are taken. Either breakfast or dinner is eliminated, depending on individual preferences. The 16/8 method is generally easy to follow, and I often recommend it to my patients.

Nutrition and mistletoe therapy

Several publications exist on the topic of an alkaline diet. As a rule, animal proteins are acidic, while plant-based products tend to have an alkaline effect on the body's metabolic processes. There are, of course, some exceptions (e.g., buttermilk is alkaline). Yet limiting – or even eliminating – one's consumption of animal products is usually a positive first step toward reducing inflammation. This approach simultaneously helps to cut back on animal fats, which also contain **proinflammatory** substances. As mentioned above, I consistently try to communicate the benefits of an organic diet that is free of toxins or pollutants to my patients.

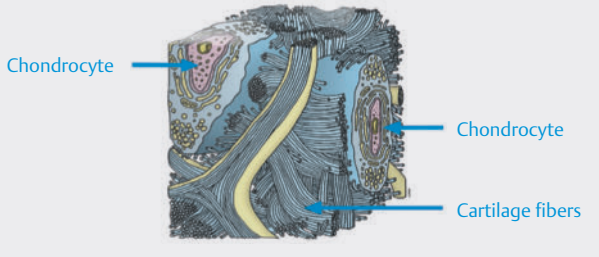

▶ **Fig. 76** Anatomy of cartilage.

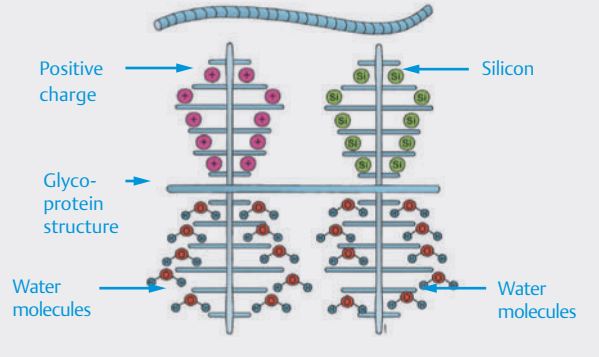

▶ **Fig. 77** Anatomy of cartilage fibers.

Particular problems can be attributed to low-quality fats often contained in industrially produced foods. People are often unaware of the detrimental effects of overheating high-quality, cold-pressed oils (e. g., olive oil) during frying. Sunflower oil contains **arachidonic acid**, which is part of an inflammatory response pathway in joints and therefore has a proinflammatory effect. Inexpensive, industrially manufactured fats contain low-quality **trans-fatty acids** that leave behind low-quality structures in the cell. Therefore, I generally try to communicate a few easy-to-follow guidelines: for frying or sauteeing, unrefined coconut or palm oil are good alternatives; butter or clarified butter (ghee) may also be used. Olive oil is an excellent option for salad dressings. Depending on individual genetics, one or two tablespoons of linseed oil, camelina oil, fish oil (including krill oil), as well as algae oil, will cover the daily requirement for omega-3 fatty acids, which have a natural **anti-inflammatory** effect. I recommend conducting a detailed analysis of fatty acid values for patients. If such an analysis reveals deficits in specific groups, oils such as pumpkin seed, walnut or sesame can be effective supplements.

Unfortunately, it is a widespread habit in our society to eat late and go to bed late. When this happens, the sleep hormone melatonin, which is vital to healthy circadian rhythms and regeneration, cannot be formed in sufficient quantities. Going to bed by 10 pm or 11 pm should thus be a regular priority – both for a good night's sleep and adequate rest and rejuvenation.

Furthermore, the growth hormone somatotropin is the only hormone capable of regenerating the body's vascular tissue. However, its production ceases whenever there are high insulin levels in the blood due to glucose absorption. This makes it advisable to avoid eating carbohydrates after six o'clock in the evening.

Nutritional supplements and mistletoe therapy

Let us first start with a few words on cartilage microstructures: specialized cells **(chondrocytes)** are responsible for the production of cartilage (actually cartilage fibers) (▶ **Fig. 76**).

Like all matrix structures, cartilage fibers consist of sugar-protein molecules (glycoproteins) and contain the minerals potassium, manganese, and above all, silicon. Their structure, consisting of several fine branches (matrix brush), is positively charged, so the individual branches repel each other like two positive poles of a magnet. The result of this structure is an extremely high water-binding capacity, accounting for the highly elastic properties of cartilage as liquids are squeezed in and out of the brushes (▶ **Fig. 77**). Certain substances within this structure are also available as nutritional supplements. Chondroitin sulfate and glucosamine are the most prominent examples. Their effects are well-documented and can be summarized as follows:

- Reduced inflammation
- Pain relief
- Support for joint metabolism
- Improved nutrient supply
- Improved cartilage regeneration
- Slowed cartilage degeneration
- Better water-binding capacity

As for recommended doses, 1500 mg of glucosamine and 1200–1500 mg of chondroitin sulfate should be taken daily for optimum results. Methylsulfonylmethane (MSM), a common ingredient in **joint supplements**, has anti-inflammatory properties as well as being a pain reliever. Here, too, make sure to prescribe the correct dose, which is 1500–1800 mg daily. I have seen good results with joint supplements taken as part of a three-month regimen, which can be prescribed up to twice a year.

To support the growth and development of collagen in cartilage, vitamin C should be present in sufficient quantities. This vitamin is also an essential requirement for good health. All cases of (joint) inflammation involve the formation of those tiny destroyers known as **free radicals**. They not only damage healthy cartilage, but also hyaluronic acid in synovial fluid and the mitochondria in chondrocytes. Vitamin C is a known antioxidant that helps capture free radicals and prevent inflammation, as does vitamin E (▶ **Fig. 78**).

Daily doses of these two vitamins administered over six to eight weeks in a 2:1 ratio (e.g., 1000 mg of vitamin C to 500 mg of vitamin E) have proven effective.

With degenerative disorders such as osteoarthritis or spinal damage, it is also crucial to assess protein levels. The **anabolic effects of protein** can and should be harnessed to promote healing. The total serum protein test can serve as a starting point, and an amino acid analysis can provide more in-depth information. I have had seen positive results after prescribing highly digestible plant proteins to my patients. Some examples include organic lupin flour, potato protein, and hemp protein.

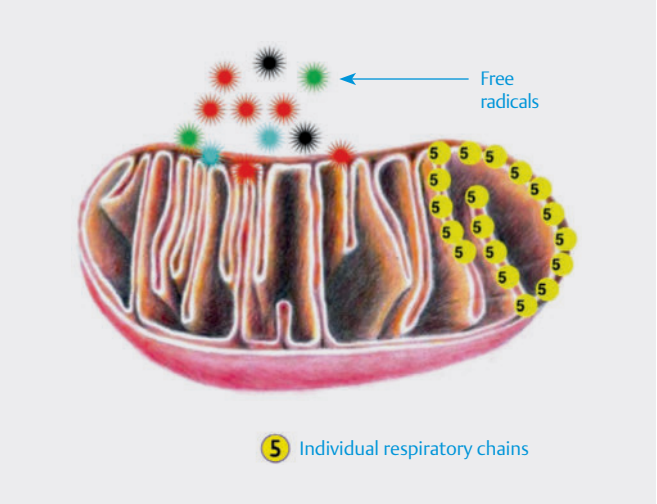

▶ **Fig. 78** Free radicals in a mitochondrion.

The Rimkus method and vitamin D

In the chapter on metabolism and mitochondrial medicine, I explained anabolic and catabolic processes. For the symptom complex of degenerative diseases, besides building blocks for cartilage production, we also need anabolic substances capable of initiating necessary construction processes in the body. These substances include reproductive hormones and the "sunshine hormone" vitamin D. Experienced practitioners and therapists who have accompanied patients – female and male – through the changes of menopause and andropause will be well-acquainted with the diverse effects of hormone deficiencies, not only in the locomotor system.

Hormone therapy is currently a heated topic in the field of gynecology due to the vast number of prescriptions issued for these substances in the 1980s and 90s. But a fact that often gets lost in the debate is that most of those compounds had a chemically modified hormone structure. Patients did not receive human endogenous, bioidentical hormones, as is currently the case in diabetes and thyroid treatments. Large-scale follow-up studies on patients who received chemically modified hormones (e. g., The Million Women Study) revealed a significant increase in the incidence of strokes, cerebral infarction, and breast and uterus cancer. Even today, there is no viable system in place to distinguish between chemically modified hormone structures and

bioidentical hormones. Consequently, hormone therapy is still widely regarded as unfavorable.

The main effects of bioidentical reproductive hormones on the locomotor system include:

- Connective tissue formation
- Cartilage and bone formation
- Stimulation of collagen development
- Stimulation of osteoblasts
- The capture of free radicals

Various systems exist to measure hormone levels, with many relying on blood and saliva. Hormone tests can be administered using different methods, whether orally, dermally, or vaginally. All procedures have their advantages and drawbacks. As therapists, we should always feel comfortable and able to identify with a chosen method. I prefer the Rimkus method, which identifies hormone levels using a blood test. Hormone substitution then takes place using a personalized Rimkus capsule. This proven approach has found a growing number of followers.

Furthermore, the “sunshine hormone” vitamin D has an anabolic effect on the locomotor system that extends beyond supporting good bone health. Recent publications have also established a link between low vitamin D levels and cancer.

In my experience, vitamin D levels ranging from 125 to 225 nanomoles per liter will provide sound protection for the locomotor system. Depending on the patient’s absorption capacity, that translates to a daily dose of 3000–9000 IU.

If patients are simultaneously taking bioidentical hormones in a Rimkus capsule, it is sensible to add vitamin D to the hormone capsule as well.

Patient information sheet on mistletoe injection acupuncture

In 1937, **Dr. med. Gerhard Madaus**, co-founder of the pharmaceutical company **MADAUS**, first introduced mistletoe therapy to the field of human medicine for the treatment of ailments of the locomotor system. Several years later, this method was still being used by numerous therapists. However, because of the emergence of new anti-inflammatory drugs, our knowledge about the effectiveness of mistletoe in treating degenerative diseases of the locomotor system was almost completely lost.

Mistletoe injection acupuncture (MIA) has proven its superiority over other treatments because it supports the body's natural processes. It has been shown to aid self-regulation and healing in osteoarthritis patients. These features distinguish MIA from conventional medical approaches that merely suppress inflammation and pain, through the use of drugs such as diclofenac or cortisone, without actively initiating the body's healing processes.

During therapy, aqueous whole plant extracts in the form of ampoules (or small vials) are used. After carefully selecting the injection points, the liquid inside the ampoules is injected into the skin, and sometimes into acupuncture channels, using extremely thin needles. On the one hand, MIA enables a permanent stimulation of the acupuncture points; on the other hand, it creates a desirable, medically induced irritation. Depending on individual response patterns, this combined stimulation *and* irritation can result in:

- Pain relief
- Muscle relaxation
- Improved metabolism
- Improved circulation
- Immunostimulation
- Cartilage regeneration
- Ligament and tendon regeneration
- Stimulation of the body's healing processes

During the injections, patients might experience a mild burning sensation. For most patients, mistletoe injections are linked to a healing reaction that may occur after each day of injection (for up to 36 hours) or only after some injection days. This response is manifested by a mild to moderate local inflammation at the injection site (intracutaneous wheal) and in some cases, a slight swelling of the skin. An immune response, with slight yet harmless swelling of local lymph nodes and a slight rise in body temperature, is possible but seldom. Occasionally, a mild increase in urine production is observable. Rare reactions include night sweats and fatigue. In one out of 10,000 cases, chills accompanied by an elevated fever and a headache may occur.

The above-described symptoms will usually subside within a few days and give way to a noticeable increase in the patient's state of health. They are ultimately the expression of a healing reaction occurring within the body.

Common reactions at the injection site, such as swelling, itchy skin, and redness, do not require any further treatment. They are desirable signs of healing. In the presence of a stronger response, cold packs can provide quick relief. If you experience any unclear symptoms, please contact your practitioner or therapist for further support.

Physicians with less experience in the area of mistletoe therapy tend to misjudge stronger reactions to mistletoe and respond with false diagnoses. The result is often unnecessary diagnostic and therapeutic measures.

MIA IS A PROMISING TREATMENT OPTION FOR THE FOLLOWING DISORDERS:

- Osteoarthritis of the major joints
- Spinal osteoarthritis
- Chronic joint pain
- Chronic spinal pain
- Migraines and dizziness linked to degenerative cervical spine disease
- Shoulder-arm syndrome
- Intercostal neuralgia
- Tennis elbow
- Degenerative disc disease
- Lumbago
- Rheumatic joint pain
- Pelvic pain
- Osteoporosis

As with all forms of treatment, before beginning a course of therapy, the physician should perform a thorough physical exam to verify the indication. An in-depth medical history to assess the patient's current metabolic condition is also recommended in order to detect and potentially treat biochemical imbalances (e.g., hyperacidic connective tissue).

In many cases, MIA can be integrated into a holistic therapy concept, for example, as part of a comprehensive biological approach to osteoarthritis or osteoporosis treatment.

Bibliography

[1] Bäumler S. Die Wirkung der Mistel bei degenerativen Erkrankungen des Bewegungsapparates – eine prospektive Falldokumentation. KIM – Komplementäre und Integrative Medizin 49, 2008, 31–37

[2] Chaplin Charlie. Film. Modern Times, 1936.

[3] Eckart A. Das Tao der Akupressur und Akupunktur, Karl F. Haug Verlag, Stuttgart 2009

[4] Elluru SR et al. Dissecting the Anti-Inflammatory Effects of *Viscum album*: Inhibition of Cytokine-Induced Expression of Cyclo-Oxygenase-2 and Secretion of Prostaglandin E2. In Zänker KS, Kaveri SV. Mistletoe – From Mythology to Evidence-Based Medicine, Karger, Basel 2015, 67–73

[5] Elsner W. Segmenttherapie peripherer Durchblutungsstörungen. Medizinische Klinik 52, 1957, 1410–1412

[6] Fliedner M. Praxishandbuch Akupunktur, Karl F. Haug Verlag, Stuttgart 1997

[7] Gleditsch JM. Reflexzonen und Somatotopien, Biologisch Medizinische Verlagsgesellschaft, Schorndorf 1994

[8] Groh H. Die Behandlung der Kniegelenkarthrose, Münchener Medizinische Wochenschrift 107, 1965, 2180–2183

[9] Heine H. Lehrbuch der biologischen Medizin, Hippokrates Verlag, Stuttgart 1997

[10] Heine H. Mistelpräparate (*Viscum album* L.) – Wirkungen auf menschliches Tumorgewebe in vitro. Zeitschrift für Phytotherapie 6, 1985, 67–72

[11] Jäger W. Die Wiederkehr der Mystik, Herder, Freiburg 2004

[12] Klopp R et al. Lokale und systemische Reaktionen auf den Funktionszustand der Mikrozirkulation und Verhaltensmerkmale weißer Blutzellen nach Anwendung von standardisiertem Mistelextrakt. DZO – Deutsche Zeitschrift für Onkologie 33, 2001, 6–14

[13] Köhler B. Grundlagen des Lebens, Books on Demand, Norderstedt 2006

[14] Kremer H. Die stille Revolution der Krebs- und AIDS-Medizin, Ehlers Verlag, Wolfratshausen 2006

[15] Kornfield J. Das weise Herz, Ariana Verlag, München 2008

[16] Loeffler H. Arthrosentherapie in der Praxis – ärztliche Erfahrungen mit Mistelpräparaten. Physikalische Medizin und Rehabilitation 21 (7), 1980, 352–353

[17] Pischinger A. Das System der Grundregulation, Karl F. Haug Verlag, Heidelberg 1975

[18] Proft D, Bartholmes P. Biosynthesis of collagen in cultured human tumor tissue under the influence of *Viscum album* extract (Abstract), Journal of Cancer Research and Clinical Oncology 115, 1989, 36

[19] Proft D. Einfluss eines Gesamtextrakts aus *Viscum album* L. auf den Kollagenstoffwechsel von peritumorösem, menschlichem Bindegewebe in Gewebekultur, Inaugural-Dissertation, Witten-Herdecke 1990

[20] Rau T. Biologische Medizin, Fonamed, Lenzburg 2007

[21] Rimkus V. Die Rimkus-Methode für die Frau, MVerlag, Mainz 2006

[22] Rimkus V. Die Rimkus-Methode für den Mann, MVerlag, Mainz 2006

[23] Schubert C. Psychoneuro-Immunologie und Psychotherapie, Schattauer Verlag, Stuttgart 2015

[24] Stange R et al. Randomized Trial with Mistletoe Injections for Osteoarthritis of the Knee in Comparison to Treatment with Diclofenac. Forschende Komplementärmedizin 7, 2000, 52

[25] Unschuld P. Ware Gesundheit, das Ende der klassischen Medizin, C.H. Beck Verlag, München 2009

[26] Wendt L. Die Eiweißspeicherkrankheiten, Karl F. Haug Verlag, Heidelberg 1984

[27] Zell J et al. Misteltherapie bei Gon- und Coxarthrose. Segment- oder Immuntherapie? Eine Pilotstudie. Heilkunst 106, 1993, 23–26